



## Critical limb ischemia: an update for interventional radiologists

Nicholas F. Brazeau, Eriqre G. Pinto, Harlan B. Harvey, George R. Oliveira, Benjamin J. Pomerantz, Stephan Wicky, Rahmi Oklu

### ABSTRACT

Critical limb ischemia (CLI) is a growing epidemic with bleak patient outcomes. A variety of treatment modalities have been adopted to address CLI based on comorbidities, life expectancy, and the nature of the arterial disease. With advances in technology and treatment strategies, the clinical outcomes of CLI patients have significantly improved over recent years. However, despite progress, patency rates of both surgical and endovascular interventions, limb-salvage and amputation rates are still dismal. We review the epidemiology, treatment strategies, imaging modalities, and the microcirculation aspect of CLI.

**P**eripheral arterial disease (PAD) is a growing health epidemic in the USA, most severely affecting persons with calorie-rich diets, diabetes, hypertension, tobacco use, and sedentary lifestyles (1, 2). Nearly 20% of all individuals 70 years or older have PAD, although the majority are asymptomatic (2, 3). Identification of asymptomatic PAD patients is crucial for early risk factor modifications given their increased risk of cardiovascular events compared to their disease-free peers (2). However, epidemiology studies have produced varying results of PAD prevalence in the general population, which only serves to emphasize the difficulty of detecting asymptomatic PAD (4). Risk factors associated with critical limb ischemia (CLI) closely mirror those of cardiovascular disease, facilitating risk stratification in asymptomatic patients (Table 1). PAD prevalence is also significant because it is the precursor of CLI, which develops in approximately 1% of all PAD cases (5).

CLI specifically refers to patients with chronic ischemic disease, defined as the presence of symptoms such as rest pain and/or ischemic skin lesions (ulcers, gangrene, etc.) for more than two weeks and is distinct from acute limb ischemia (4). It is manifested by severe, occlusive arterial disease and is most often associated with peripheral atherosclerosis, although trauma, vasculitis, and hypercoagulable processes can also result in CLI (4–6). CLI patients are generally classified at the severe end of the vascular disease spectrum in Rutherford categories 4 to 6 and Fontaine Stages III to IV (Table 2) (4, 5, 7). The progression from PAD to CLI in patients corresponds with a greater risk for cardiac ischemic events, and subsequently, CLI patients experience significant morbidity and mortality from cardiovascular events or complications (5, 8). The resultant economic burden of CLI is significant, accounting for an estimated \$10–20 billion of healthcare expenditures per year in the USA alone (9). CLI incidence and the associated economic burden are expected to rise as the baby boomer population ages and diabetes prevalence increases (9).

Early and accurate diagnosis, risk factor modifications, and PAD monitoring are imperative for patient survival, particularly because CLI revascularization and intervention are most effective in the setting of healthy distal limb tissues (5, 10). Of those CLI patients in whom revascularization is not possible, a quarter will die, and another quarter will undergo a major amputation within a year of the initial diagnosis (4).

Clinically, CLI is manifested by resting ischemic pain, tissue death (e.g., extremity ulcers), and compromised hemodynamics (e.g., cold extremities) (1, 5, 11). The most widely accepted explanation of CLI proposes that the vascular pathology results from a prolonged, chronic imbalance of vascular supply versus demand (5, 12). Under this model, a hemodynamically significant proximal arterial occlusion reduces distal perfusion for an extended period of time, resulting in the accu-

From the Department of Vascular Imaging and Intervention (N.F.B., H.B.H., G.R.O., S.W., R.O. ✉ [rahmioklu@gmail.com](mailto:rahmioklu@gmail.com)), Massachusetts General Hospital, Harvard Medical School, Boston, Massachusetts, USA; the Department of Imaging (E.G.P.), Hospital Professor Doutor Fernando Fonseca, Amadora, Portugal; the Department of Radiology (B.J.P.), Kalispell Regional Medical Center, Kalispell, Montana, USA.

Received 17 April 2012; revision requested 20 May 2012; revision received 29 June 2012; accepted 2 July 2012.

Published online 30 November 2012  
DOI 10.4261/1305-3825.DIR.5955-12.1

**Table 1.** Associated risk factors and relative risks of critical limb ischemia (4)

Risk factors		Relative risk
Diabetes mellitus		4
Tobacco smoking		3
Ankle-Brachial Index	<0.7	2
	<0.5	2.5
Age (over 65 years)		2
Lipid abnormalities		2

**Table 2.** Rutherford and Fontaine classifications for peripheral arterial disease (4, 5)

Grade	Rutherford		Fontaine	
	Category	Clinical presentation	Stage	Clinical presentation
0	0	Asymptomatic	I	Asymptomatic
I	1	Mild claudication	IIa	Mild claudication
	2	Moderate claudication	IIb	Moderate to severe claudication
	3	Severe claudication		
II	4	Ischemic pain at rest	III	Ischemic rest pain
III	5	Minor tissue loss	IV	Leg ulcers or gangrene
	6	Major tissue loss		

mulation of metabolic waste, hypoxia and oxidative stress, which eventually compromises normal vascular and physiological functions (5, 12). Thus, the likelihood that tissues distal to the occlusion will remain viable depends on the location, duration, and severity of the occlusive disease and the extent of collateral blood flow. Lending support to this explanation are endogenous mechanisms that respond to ischemia to preserve tissue viability by attempting to increase the perfusion of the ischemic tissue through the formation of new collaterals (i.e., angiogenesis) and vasodilation of existing collaterals. However, these endogenous reperfusion mechanisms may further exacerbate regions of inadequate tissue perfusion, for example, by causing tissue edema (5).

### Diagnosis

The Inter-Society Consensus (TASC) II guidelines provide an international consensus for the diagnosis and management of patients with PAD (4). In addition to a thorough history and physical exam, multiple noninvasive hemodynamic parameters were proposed by these guidelines to support the diagnosis of CLI. These hemodynamic tests include measurements of ankle

pressure (<50–70 mmHg), toe pressure (<30–50 mmHg), and transcutaneous oxygen tension (30–50 mmHg) (4). Commonly used imaging techniques to characterize the extent of the peripheral vascular disease in this setting include duplex ultrasonography, digital subtraction angiography (DSA), magnetic resonance (MR) angiography, and computed tomographic (CT) angiography. Despite the challenges associated with CLI, outcome measures such as treatment-related mortality, amputation rates, and postprocedural hospital stays have all improved over the past decade. These incremental successes are likely due to new treatment strategies in combination with technological advancements.

For the evaluation of CLI, a growing emphasis has been placed on the status of the tibial arteries. However, the small caliber and low flow within the tibial arteries compared to proximal, larger arteries present unique imaging challenges. With these challenges in mind, the common modalities for CLI diagnosis are discussed below.

#### Digital subtraction angiography

DSA is considered the gold standard imaging technique for the evaluation

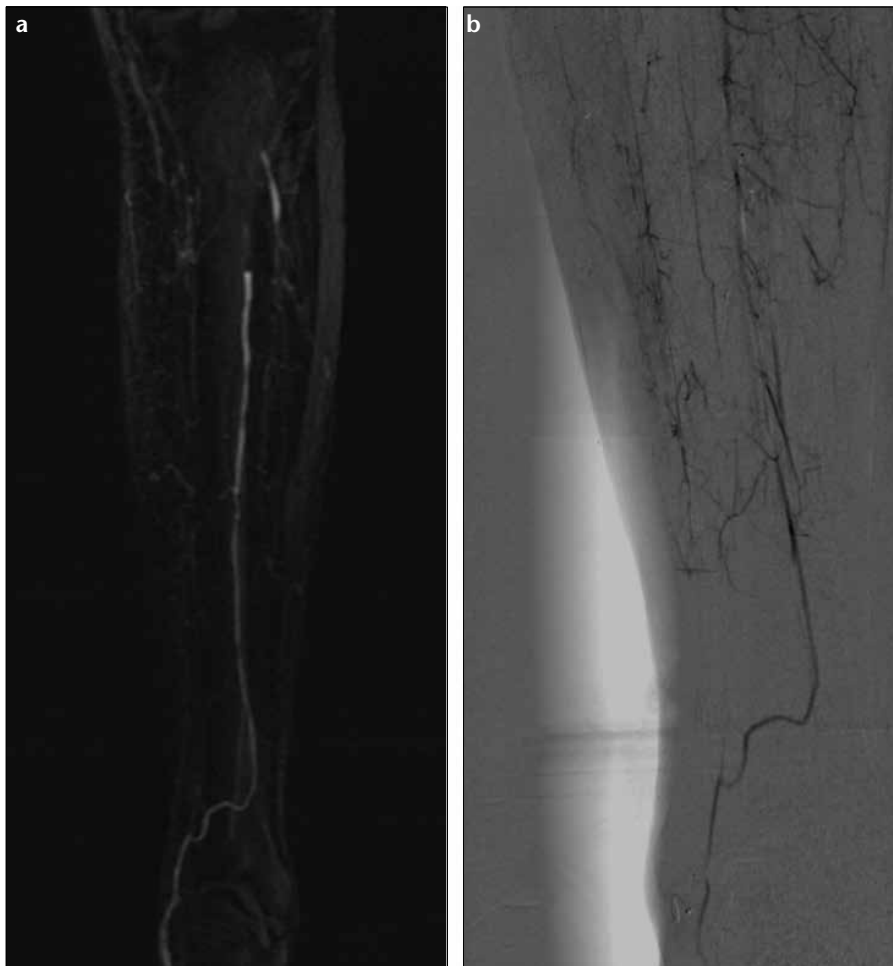
of PAD. Hemodynamically significant lesions reduce the luminal diameter of the artery by 50% or more, which often corresponds to a pressure gradient of 10–15 mmHg (4). The TASC II guidelines categorize femoropopliteal lesions depending on their severity and anatomical location. An endovascular approach is the treatment of choice for type A lesions, whereas surgery is the treatment of choice for type D lesions. Endovascular therapy and surgery are the preferred treatments of lesions in categories B and C, although the choice here depends upon the operator and any comorbidities that may be present (4).

DSA carries the risk of anaphylactic reaction to the commonly used iodinated contrast medium (0.7%) as well as the risk of mortality (0.16%). Arterial dissection, atheroemboli, contrast-induced renal failure, and access site complications such as pseudo-aneurysms, hematomas, and arteriovenous fistulas can also occur, although these complications have been partially addressed by technological advances and the use of alternative contrast medium (i.e., carbon dioxide and gadolinium-based contrast medium). Furthermore, DSA only provides a limited two-dimensional plane of view of the lesions and often requires prolonged imaging to view pedal vessels and collaterals in the setting of an arterial occlusion, increasing the radiation dose to the patient (4).

#### MR angiography

Though the “gold standard” for PAD diagnosis has conventionally been DSA, MR angiography is recognized as a cheaper, faster, and safer diagnostic alternative (13). Moreover, advances in MR angiography technology, such as the improvements of signal-to-noise ratio techniques driven by a combination of hardware development, better gradients and receiving coils, and the increased use of gadolinium as a contrast agent, continue to make MR angiography based evaluation of the smaller vessels of the leg an even more attractive diagnostic option (Fig. 1).

Recent studies indicate that three-dimensional (3D) MR angiography angiography is comparable to conventional angiography in the evaluation of vascular disease. For instance, a pilot study of 3D MRA showed a 77% overall sensitivity and 94% specificity to iden-



**Figure 1. a, b.** Lower extremity angiography by MRI and DSA in the same patient. MRI (a) accurately depicts single vessel run-off to the foot and allows multiplanar views for a complete assessment. DSA (b) of the same leg provides limited information of the run-off from its proximal extent and allows only limited views, often necessitating additional DSA sequences, which increases the radiation dose delivered to the patient.

tify the occlusion, when compared with conventional angiography (14). Moreover, in 23% of the cases, 3D MR angiography detected flow that angiography did not (14). Similarly, in a separate study on pedal vascular imaging, 3D MR angiography was shown to offer a better representation of the CLI anatomy in the calf and pedal regions than DSA, and even afforded sub-millimeter voxel views (15). Furthermore, the recent introduction of blood pool MR angiography contrast agents have provided a more robust assessment of smaller vessels when compared to the more quickly cleared magnetic resonance imaging (MRI) contrast agents such as gadopentetate dimeglumine (Magnevist, Bayer, Leverkusen, Germany). Of these MR angiography blood contrast agents, only gadofosveset trisodium (Ablavar or Vasovist, Lantheus

Medical Imaging, North Billerica, Massachusetts, USA), is FDA approved and is the first gadolinium-based MR angiography blood pool agent to be marketed in the USA (16). By binding reversibly to human albumin, gadofosveset is more slowly cleared from the blood supply. Advantages of MRI blood pool agents, such as Ablavar, in the assessment of small vasculature include higher resolution, higher signal per dose, longer imaging window time frame, and single-dose imaging of multiple vessel beds (17). Data collected from four phase 3 clinical trials showed that MR angiography enhanced with gadofosveset agreed with conventional catheter angiography in most cases and had an overall accuracy that was greater than noncontrast, time-of-flight MR angiography (18). Additionally, a recent trial demonstrated that

gadofosveset-enhanced MR angiography offers a diagnostic accuracy that is comparable to DSA in the lower limb (19). However, there are disadvantages to MR angiography compared to DSA, including compromises in signal intensity in heavily stenotic regions, more limited spatial resolution and the risk of gadolinium-associated nephrogenic systemic fibrosis in patients with renal failure (13, 20). Importantly, to date, gadofosveset has not shown an association with nephrogenic systemic fibrosis. This lack of an association may possibly be related to the comparatively smaller dosage of gadolinium in gadofosveset when compared to magnevist, which makes it an attractive alternative given the high coincidence of small vessel disease and renal failure in these patients.

#### CT angiography

In the clinical setting, CT angiography represents an alternative imaging modality for PAD and CLI. CT angiography is able to cover large areas at higher speeds while still retaining a high degree of resolution (21). Furthermore, CT angiography may be an attractive option for some patients as it is less expensive than MR angiography, but may still be able to offer comparable results. For instance, a recent study on PAD evaluation failed to demonstrate significant differences in patient outcome between CT angiography and MR angiography modalities (22).

CT angiography scans are now largely done with the aid of the multi-detector-row computed tomography (MDCT) technique, with sensitivities and specificities ranging from 90%–99% (23). Additionally, helical acquisition MDCT allows for better calculation of blood velocities and can produce extremely accurate images with high resolution 128-slice 3D reconstruction (24). However, to obtain an optimal study, the duration of the injection should be correlated to arterial transit speed (25). Other methods of overcoming conventional CT angiography limitations have been to employ time-resolved CT (TR-CT) angiography, which has been shown to provide better images in the calves and lower leg regions (26).

Recently, CT angiography detection of PAD has been further improved through the use of dual-energy CT (DE-CT) angiography, producing a specificity of 94.1%, sensitivity of

97.2%, and accuracy of 94.7% when compared with DSA; all of these values exceed DSA reported values by at least 20% (23). DE-CT angiography employs two CT scanners with differing tube voltages, allowing for subtle density differences to be exploited to provide more accurate differentiation between iodine contrast, soft tissue, bones, and vessel wall (23). Similarly, another improvement to CT angiography imaging has come through the development of arterial-specific algorithms, which can allow for more precise evaluation of the shape and layout of the arteries. In a recent study, Raman et al. (27) developed an algorithm that combined arterial wall thickness and flow-path data to generate reliable calculations of noncalcified plaque size: reports indicated an absolute error of only  $1.9 \pm 2.3\%$  and an inter-observer variability of  $3.9 \pm 3.6\%$ . This algorithm could provide clinicians with an optimal prognostic tool, as it may be used to measure potential plaque formation in asymptomatic patients who may later develop PAD and CLI.

A major pitfall of CT angiography is

the lack of resolution produced when evaluating vascular segments containing moderate-to-severe calcifications or metallic stents. Use of appropriate windowing (approximately 1500 window width) may be helpful to reduce the artifact caused by high signal structures, such as calcified vessels. Another disadvantage of CT angiography is the use of ionizing radiation; however, the radiation doses are significantly lower than invasive catheter angiography.

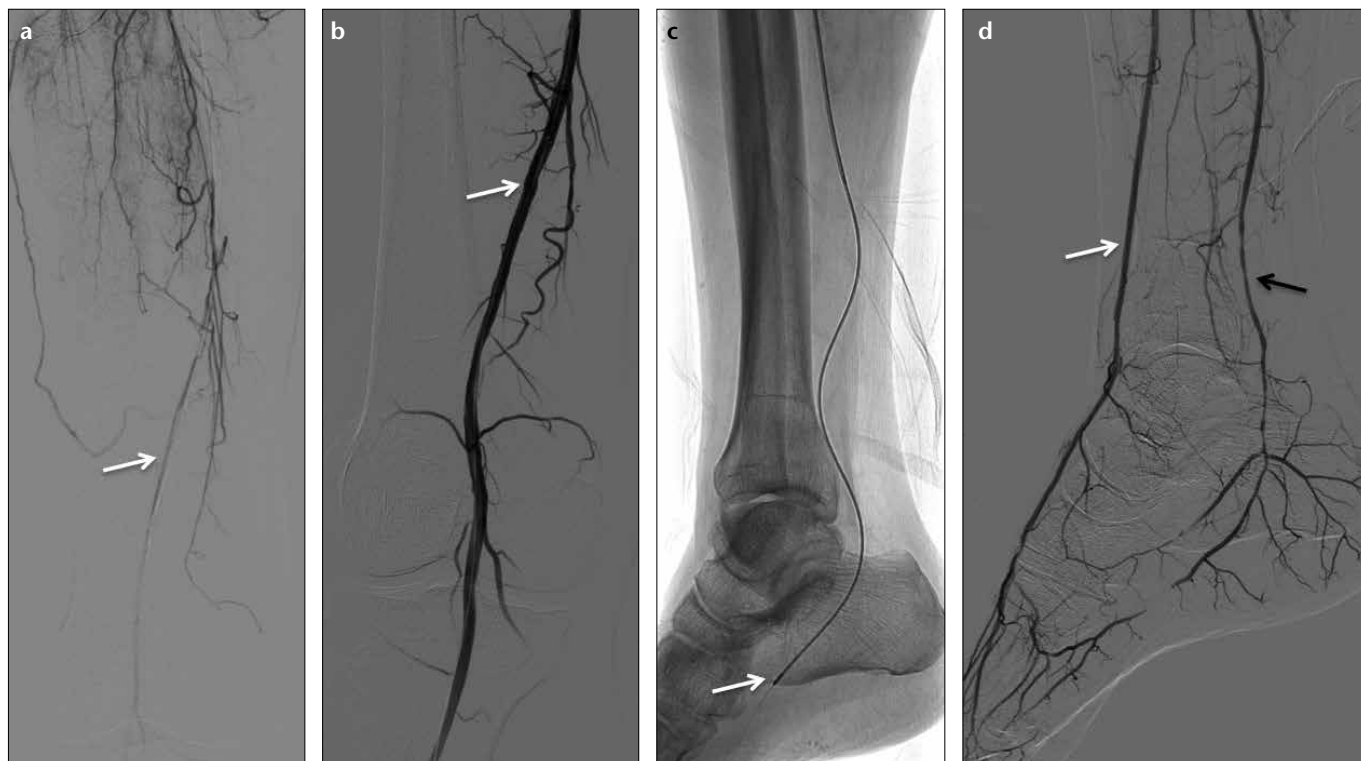Overall, CT angiography and MR angiography are ideal for noninvasive, preoperative assessment in many situations and have generally replaced DSA, though DSA still remains the "gold standard" for PAD diagnosis (23).

### Treatment

Generally speaking, the overarching treatment goal of CLI is arterial revascularization and limb preservation. However, clinical management must be tailored to a patient's risk-benefit profile and prognosis because not all patients who undergo a revascularization procedure will achieve positive clinical outcomes (5, 12). Clinical results may be

compromised by ischemic-reperfusion injury, capillary injury or disease, or insufficient capillary perfusion, which can occur despite adequate proximal arterial revascularization (28, 29). In patients with failed revascularization attempts, 40% will undergo amputation, and 20% will die within six months of CLI presentation (4). Great care needs to be taken when choosing the level of amputation to ensure wound healing and preserve adequate limb length to accommodate a prosthesis; individuals with an above-the-knee amputation have a likelihood of independent ambulation less than 50% (4). Overall, however, the long-term prognosis of below-the-knee amputation is grim, with only 30% surviving after two years of the first major amputation (4).

In conjunction with these dismal prognoses, the advent of new and efficacious treatment options have reshaped patient treatment discussions and have further fueled the debate of the most appropriate CLI treatment strategy: surgical bypass versus endovascular techniques. Although surgical bypass of the infrainguinal arteries us-



**Figure 2.** a–d. A 62-year-old patient being investigated for nonhealing ulcerations in the foot. DSA (a) demonstrates complete occlusion of the superficial femoral artery with extensive collateral vascularization and reconstitution of the distal outflow as indicated by the white arrow. Superficial femoral artery (b) was revascularized (white arrow) following extensive percutaneous transluminal angioplasty (PTA) and placement of a covered stent. Run-off to the foot (c) proceeded via the peroneal artery. Both the anterior and posterior tibial arteries were revascularized using a combination of PTA and atherectomy. The atherectomy device is indicated by the white arrow (c). DSA (d) demonstrates marked improvement of flow to the foot via successful revascularization of the anterior (white arrow) and posterior (black arrow) tibial arteries.

ing autologous veins has and continues to be considered the most favorable treatment for CLI, endovascular techniques, including percutaneous transluminal angioplasty (PTA), have improved and now rival surgical bypass in terms of patient risk factors (11, 30, 31) (Fig. 2). The merits of each treatment strategy are discussed below.

#### *Surgical management*

Studies have demonstrated that open surgical bypass produces the best long-term patency rates, with the use of the autologous saphenous vein serving as “the gold standard” (32). However, to date, the Bypass versus Angioplasty in Severe Ischemia of the Leg (BASIL) trial remains the only randomized prospective trial comparing the success of open surgical bypass versus endovascular therapy for CLI (7). BASIL included 452 patients who underwent either primary interventional angioplasty or bypass surgery and were followed until an amputation above the ankle or death occurred (7, 33). At 12 months, only 107 of 216 patients (49.5%) who had received angioplasty maintained clinical success, compared to 110 of 195 patients (56.4%) undergoing surgical procedures (32, 33). The initial BASIL report found that amputation-free survival and quality of life rates were similar in both groups at six months (33). However, in the long-term, for patients who survived beyond two years, surgery offered a significantly increased overall survival benefit of approximately seven months (5, 7). Despite superior outcomes, the option of surgical repair remains limited to a select cohort of patients healthy enough to withstand an invasive procedure. Based on this trial of operable candidates, only those patients with life expectancies greater than two years are likely to realize a survival benefit from surgery compared to angioplasty (7).

Similar estimates for bypass surgery clinical outcomes are revealed in the PREVENT III study, a multicenter phase 3 study, demonstrating primary patency, primary assisted patency, secondary patency, and limb salvage rates in 61%, 77%, 80%, and 88% of patients at one year, respectively (5, 34). The PREVENT III study also produced a risk scoring method that places surgical bypass candidates into low-, mid-, or high-risk patient groups depending on other indications, such as age and comorbidities (35, 36).

Given the current data, therapeutic decisions regarding CLI generally hinge on whether a patient can withstand invasive surgery, the availability of an autologous saphenous vein and the patient’s life expectancy. However, given the complexities of the current healthcare environment, cost concerns are increasingly factoring into clinical decisions. A recent manuscript considering cost implications of surgical versus endovascular management of CLI demonstrated that while there are initial cost benefits to endovascular management, open surgical procedures are more cost-effective over the long-term when cost per patient-day of patency was used as a proxy for overall treatment costs (37). Thus, open surgery may hold cost benefits in addition to survival benefits for patients who are surgical candidates with life expectancies of greater than two years.

#### *Endovascular therapy*

PTA remains a less invasive option and is preferred for nonsurgical candidates and for surgical candidates whose life expectancy is less than two years (12). Although endovascular therapy offers reduced morbidity, decreased lengths of hospital stay, and lower initial costs compared to bypass surgery, it is unable to provide the primary patency durability of open repair (5, 12, 35, 38). For example, PTA patency for primary tibial artery disease has been demonstrated to be as low as 20%–60% (38). However, these patency rates are for traditional PTA techniques, which may prove inferior to newer endovascular techniques.

A study comparing endovascular and surgical techniques for the treatment of severe aorto-iliac occlusive disease revealed that while the surgical approach benefits from a higher primary patency rate (89% vs. 100%), secondary patency rates are similar (96% vs. 96%) at three years after the procedure (39). Kedora et al. (40) also described their experience with self-expandable stents versus femoral-popliteal above the knee bypass, reporting similar limb salvage, with comparable primary (73.5% vs. 74.2%) and secondary patency rates (83.9% vs. 83.7%) at one year with both techniques. Lepantalo et al. (17), however, reported significantly lower patency rates for stent grafts compared to bypass surgery, with a peri-operative mortality rate of 2.7%, resulting

in the premature termination of their randomized clinical trial. Other studies also reported that despite the reduced primary patency, limb salvage rates remain comparable to surgical bypass and range from 74% at five years to 84.7% at eight years (41–43).

In a recent meta-analysis of infra-popliteal angioplasty for CLI (44), estimates of primary patency, secondary patency, and limb salvage rates up to 36 months demonstrated a lower durability of infra-popliteal angioplasty when compared to popliteal-to-distal bypass graft. More importantly, the meta-analysis revealed that the clinical benefit is acceptable because the limb salvage rate (82%) at three years was comparable to that of surgical revascularization. Repeated interventions were much more frequent in endovascular procedures than with bypass grafts; however, the main advantage is that the latter is increasingly less feasible (44).

A recent drug eluting stent trial, Preventing Amputations using Drug Eluting Stents (PaRADISE) analyzed the largest published cohort of CLI patients (Rutherford-Becker scale category 4 or greater) undergoing below-the-knee primary drug eluting stent placement. At three-years postprocedure, the results were promising, with an amputation rate of only 6±2%, an amputation-free-survival of 68±5%, and an overall survival of 71±5% (38). Moreover, the PaRADISE study reported a 13±3.6% increase in leg salvage rates over the BASIL trial at three years, although this comparison is limited by significant differences in study design (38). Another study examined the efficacy of laser-assisted angioplasty (Spectranetics, Colorado Springs, Colorado, USA) on 145 CLI patients (Rutherford category of 4 and greater) who did not qualify for surgical reconstruction (8, 30). After laser atherectomy, 110 of the limbs received PTA, and 70 limbs underwent stent placement. Procedural success, defined as less than 50% residual stenosis, was achieved in 86% of these limbs, and at six months, patient survival and limb salvage rates were 92% and 93%, respectively (8). These results offer encouragement to a cohort of patients with limited options who face bleak prognoses (8). Recent reports have demonstrated the broadening applicability of endovascular techniques in the ability to treat increasingly complex femoropopliteal

and infrapopliteal lesions, which until recently were considered unapproachable by endovascular techniques (45).

Given the promising endovascular therapy results, Conrad et al. (41) proposed a similar, less invasive treatment procedure involving first-line, palliative PTA treatment with the intention to perform a secondary intervention to maintain patency. This multistage approach has largely been considered only in the aging patient population where open bypass surgery is a less favorable option (41). Under this consideration, the CLI treatment strategy is shifted towards palliative stent placement with expected secondary patency procedures, and open surgery is limited to patients who have dismal angioplasty results or who do not qualify for endovascular treatment (41, 46).

#### *Medical management following revascularization*

In CLI, aggressive systemic cardiovascular risk reduction, including cholesterol reduction, anti-hypertensives, smoking cessation, and tight glycemic control, should be applied where necessary, regardless of any revascularization attempts (4). Amputation rates at 12 months postPTA improved from 21.1% in patients receiving 250 mg acetylsalicylic acid (ASA) to 11.1% when 20 mg lovastatin was used in conjunction with 250 mg ASA (47).

The most effective postoperative anti-thrombotic regimen is contentious. Platelet inhibition is preferable following PTA when compared to vitamin K antagonists (48). Currently, long-term aspirin (75–100 mg) or clopidogrel (75 mg) is recommended following PTA, as this has been shown to improve revascularization patency; however, there is no evidence that this regimen improves outcomes in CLI (4, 49). Higher doses of aspirin (300–1000 mg) failed to significantly improve patency rates and were associated with higher rates of gastrointestinal side effects (50). Following successful PTA, patients who received three months of 2500 IU deltaparin in addition to 100 mg aspirin daily exhibited a reduction in restenosis at one year compared to those who only received 100 mg aspirin. (45% vs. 72%;  $P = 0.01$ ). However, the addition of deltaparin only had a beneficial effect when patients had undergone PTA for CLI; in less severe PAD, the addition of deltaparin conferred no benefit

(47). The use of thienopyridines (clopidogrel and ticlopidine) as an alternative or in combination with aspirin may be a useful alternative, but data are currently lacking (51).

The optimal anti-thrombotic medication for surgical bypass patients depends on the type of graft used. Restenosis of venous grafts was best prevented when oral vitamin K antagonists were used (target international normalized ratio, 3.0–4.5), whereas aspirin produced superior results for synthetic grafts (52).

#### **Below-the-knee disease—a unique subset of CLI**

Below-the-knee (BTK) endovascular therapies that address popliteal occlusions are generally complex because lower distal pressures and numerous comorbidities can often complicate procedural techniques. Bypass surgery is generally not used in the elderly CLI population due to increased morbidity, mortality, and associated risks of BTK tibial bypass, which include high rates of graft failure, procedural mortality, and the risk of a failed procedure, considerably worsening the CLI condition (53). Limb salvage, a major goal of CLI procedures, is related to successful dilation of all critical inflow lesions and a vertical, contiguous outflow to one or more tibial arteries that is not limited to the pedal arch.

The angiosome model is being increasingly applied in CLI, resulting in clinical benefits when the model is used to direct therapy. The angiosome concept was originally proposed by Taylor and Palmer in 1987 and emphasizes a multivascular approach to CLI. When applied, it has led to improved limb salvage rates, healing rates and amputation free survival rates (54, 55). The angiosome concept renders the body into a 3D vascular territory of “composite units,” which correspond to areas that vascularize the underlying tissue and skin layer (55). Taylor and Pan (56) later defined the angiosomes in the lower leg, which if considered during the revascularization stages of treatment, may be able to aid in wound or amputation healing via the patency of the particular vessel and collateral vascular supply of the angiosome. However, despite these considerations, BTK procedures are still afflicted by low patency rates, with one-year patency rates as low as 58% (38). Moreover, given the high rate of resteno-

sis, stent placement in the crural arteries is generally reserved in clinical practice for bailout procedures after balloon PTA failure (residual stenosis or flow limiting dissection) (57). However, in 2004, primary stent placement was proposed in BTK patients by Feiring et al., (53) who reported a 95% success rate, defined as relief of ischemic pain and tissue healing. This was the first study to support primary stent placement in the lower extremities. More recently, studies have also demonstrated that balloon PTA procedures can result in a 77%–100% technical success rate in BTK intervention (11). Furthermore, the recent introduction of long, low profile angioplasty balloon catheters and microwire systems have improved endovascular treatment approaches by extending the range of lesions that are treatable with a primary endovascular technique (11). One study of 58 patients treated with long low-profile 80 - to 120-mm angioplasty balloons reported a 15-month 100% limb salvage rate (11).

However, it is well established that balloon PTA procedures in BTK patients encounter significant patency problems in the long-term, with one-year patency rates as low as 58% (38). Technical skills, device type, and entry site all affect the treatment success of BTK endovascular therapy. Additionally, tissue healing is more demanding of the arterial supply than ulcer prevention, which may explain why the short-term benefits of a stent outweigh the benefits for low long-term patency rates. Other advances, such as cryoplasty and laser-assisted recanalization techniques, have not been fully accepted to date. There is increasing interest in debulking atherectomy in the infrapopliteal arteries. Several device companies are producing small atherectomy devices intended for use in the tibial vasculature and even within the pedal circulation (Fig. 2). Given the paucity of long-term patency data in patients treated with these devices, the extent to which lesion debulking decreases limb loss and improves quality of life is unknown, as is the durability of these results.

#### **Measures of success and quality of life**

The success of endovascular therapy is described by patency and amputation-free survival rates. However, with the advent of newer and less invasive tools, the safety and efficiency of each

procedure should also be considered in determining the best treatment strategy. One study examined the safety standard of all percutaneous lower extremity techniques, including atherectomy devices, primary PTA and PTA with stent placement, by evaluating the likelihood of a given procedure producing a distal embolic event (58). In this study, the Jetstream Atherectomy Catheter and the Diamondback 360 catheter were associated with significantly greater embolization rates than other tested treatment modalities (58). Embolic protection devices, primarily used with carotid artery stenting, are available, and some can be used with both the Jetstream and Silverhawk atherectomy catheters.

When successful, limb salvage procedures may offer financial advantages. For instance, the postoperative medical costs of care for an amputee are considerable and have been estimated as two times greater than the costs of operative and postoperative care (5, 9). Unfortunately, CLI patients commonly suffer from associated comorbidities such as renal disease and diabetes mellitus, which are associated with decreased rates of limb salvage (5, 12). The microvascular and small-vessel diseases associated with CLI likely explain the poor clinical outcomes despite revascularization and may serve as an important prognostic indicator of treatment success. Thus, there is a need for innovative diagnostic techniques that can afford views of the smaller arterial vessels and, if possible, the capillary bed to allow for better patient selection.

### Microcirculation

Microcirculation is often characterized as the system of vessels that includes the arterioles, the capillaries, the venules, and the lymphatic vessels. Skin microvessels, in particular, have recently been suggested to be good indicators for evaluating systemic vascular diseases, including CLI (59). Noticeably, CLI patients often present with edema, a possible result of compromised capillary vasomotor responses, which lead to capillary hypertension and excess fluid filtration (59).

The endothelium, lining the inner surface of all vessels, plays a crucial role in maintaining vascular hemostasis, and its dysfunction is recognized as an early sign of common vascular

pathologies such as atherosclerosis, inflammation, and thrombosis. Under normal conditions, the endothelium is in a quiescent state and has a normal morphology. The blood flows unperturbed as the leukocytes and platelets are in a nonsecretory and nonadherent state. However, in symptomatic patients with intermittent claudication, exercise can elicit a symptomatic response, causing a reduction in the blood flow to ischemic areas with a subsequent acute reduction of perfusion pressure (60). The endothelium reacts to ischemia by becoming pro-thrombotic, activating the coagulation cascade and promoting platelet adhesion (60). It also expresses adhesion molecules favoring leukocyte, erythrocyte and platelet plugging, resulting in increased blood viscosity (60). Furthermore, while leukocyte and platelet activation may pose a physical obstruction in microcirculation, activated leukocytes can also release noxious chemicals, including proteolytic enzymes, oxygen free radicals and leukotrienes, which promote further endothelial damage, thereby increasing vascular permeability and plasma leakage (60). As a result, these contributors can act as a self-perpetuating model that promotes endothelial injury and increases in vascular permeability, resulting in fluid leakage, interstitial edema and local capillary collapse and further exacerbating the compromised capillary hemodynamic system. Endothelial dysfunction also results in the failure of endothelium-mediated mechanisms of vascular tone regulation, such as the synthesis of nitrous oxide.

The relationship between the macroscopic angiographic appearance and microcirculation as well as the impact of postural changes to the microcirculation and how those changes can help better predict the need for amputation, continues to be poorly understood and visualized.

### Conclusion

Ischemia necessitates an aggressive treatment plan to restore proper hemodynamic flow if tissue death and infection are to be avoided. As a result, the development of CLI requires immediate action towards revascularization. However, successful treatment will likely hinge on individual patient evaluations; multiple factors including age, comorbidities, and quality of life

will all need to be considered to select the best treatment option.

### Conflict of interest disclosure

The authors declared no conflicts of interest.

### References

- Egorova NN, Guillerme S, Gelijns A, et al. An analysis of the outcomes of a decade of experience with lower extremity revascularization including limb salvage, lengths of stay, and safety. *J Vasc Surg* 2010; 51:878–885. [\[CrossRef\]](#)
- Bashir R, Cooper CJ. Evaluation and medical treatment of peripheral arterial disease. *Curr Opin Cardiol* 2003; 18:436–443. [\[CrossRef\]](#)
- Stewart KJ, Hiatt WR, Regensteiner JG, Hirsch AT. Medical progress: exercise training for claudication. *N Engl J Med* 2002; 347:1941–1951. [\[CrossRef\]](#)
- Norgren L, Hiatt WR, Dormandy JA, et al. Inter-Society Consensus for the Management of Peripheral Arterial Disease (TASC II). *J Vasc Surg* 2007; 45:5–67. [\[CrossRef\]](#)
- Varu VN, Hogg ME, Kibbe MR. Critical limb ischemia. *J Vasc Surg* 2010; 51:230–241. [\[CrossRef\]](#)
- Gottsater A. Managing risk factors for atherosclerosis in critical limb ischaemia. *Eur J Vasc Endovasc Surg* 2006; 32:478–483. [\[CrossRef\]](#)
- Conte MS. Bypass versus Angioplasty in Severe Ischaemia of the Leg (BASIL) and the (hoped for) dawn of evidence-based treatment for advanced limb ischemia. *J Vasc Surg* 2010; 51:69–75. [\[CrossRef\]](#)
- Laird JR, Zeller T, Gray BH, et al. Limb salvage following laser-assisted angioplasty for critical limb ischemia: results of the LACI multicenter trial. *J Endovasc Ther* 2006; 13:1–11. [\[CrossRef\]](#)
- Allie DE, Hebert CJ, Ingraldi A, Patlola RR, Walker CM. 24-carat gold, 14-carat gold, or platinum standards in the treatment of critical limb ischemia: bypass surgery or endovascular intervention? *J Endovasc Ther* 2009; 16:134–146. [\[CrossRef\]](#)
- Blevins WA, Schneider PA. Endovascular management of critical Limb Ischemia. *Eur J Vasc Endovasc Surg* 2010; 39:756–761. [\[CrossRef\]](#)
- Yan BP, Moran D, Hynes BG, Kiernan TJ, Yu CM. Advances in endovascular treatment of critical limb ischemia. *Circ J* 2011; 75:756–765. [\[CrossRef\]](#)
- Slovut DP, Sullivan TM. Critical limb ischemia: medical and surgical management. *Vasc Med* 2008; 13:281–291. [\[CrossRef\]](#)
- Grijalba FU, Esandi MC. Comparison of gadofosveset-enhanced three-dimensional magnetic resonance angiography with digital subtraction angiography for lower-extremity peripheral arterial occlusive disease. *Acta Radiol* 2010; 51:284–289. [\[CrossRef\]](#)
- Sommerville RS, Jenkins J, Walker P, Olivetto R. 3-D magnetic resonance angiography versus conventional angiography in peripheral arterial disease: pilot study. *ANZ J Surg* 2005; 75:373–377. [\[CrossRef\]](#)

15. Langer S, Kramer N, Mommertz G, et al. Unmasking pedal arteries in patients with critical ischemia using time-resolved contrast-enhanced 3D MRA. *J Vasc Surg* 2009; 49:1196–1202. [\[CrossRef\]](#)
16. Jongen VH. Alternative external fixation for open fractures of the lower leg. *Trop Doct* 1995; 25:173–174.
17. Lepantalo M, Laurila K, Roth WD, et al. PTFE bypass or thrupass for superficial femoral artery occlusion? A randomised controlled trial. *Eur J Vasc Endovasc Surg* 2009; 37:578–584. [\[CrossRef\]](#)
18. Goyen M. Gadofosveset-enhanced magnetic resonance angiography. *Vasc Health Risk Manag* 2008; 4:1–9. [\[CrossRef\]](#)
19. Bonel HM, Saar B, Hoppe H, et al. MR angiography of infrapopliteal arteries in patients with peripheral arterial occlusive disease by using Gadofosveset at 3.0 T: diagnostic accuracy compared with selective DSA. *Radiology* 2009; 253:879–890. [\[CrossRef\]](#)
20. Buhaescu I, Izzedine H. Gadolinium-induced nephrotoxicity. *Int J Clin Pract* 2008; 62:1113–1118. [\[CrossRef\]](#)
21. Foley WD, Stonely T. CT angiography of the lower extremities. *Radiol Clin North Am* 2010; 48:367–396. [\[CrossRef\]](#)
22. Ouwendijk R, de Vries M, Pattynama PMT, et al. Imaging peripheral arterial disease: a randomized controlled trial comparing contrast-enhanced MR angiography and multi-detector row CT angiography. *Radiology* 2005; 236:1094–1103. [\[CrossRef\]](#)
23. Brockmann C, Jochum S, Sadick M, et al. Dual-energy CT angiography in peripheral arterial occlusive disease. *Cardiovasc Intervent Radiol* 2009; 32:630–637. [\[CrossRef\]](#)
24. Kumamaru KK, Hoppel BE, Mather RT, Rybicki FJ. CT angiography: current technology and clinical use. *Radiol Clin North Am* 2010; 48:213–235. [\[CrossRef\]](#)
25. Shimizu K, Utsunomiya D, Nakaura T, et al. Uniform vascular enhancement of lower-extremity artery on CT angiography using test-injection monitoring at the central level of the scan range: a simulation flow phantom study with clinical correlation. *Acad Radiol* 2010; 17:1153–1157. [\[CrossRef\]](#)
26. Sommer WH, Helck A, Bamberg F, et al. Diagnostic value of time-resolved CT angiography for the lower leg. *Eur Radiol* 2010; 20:2876–2881. [\[CrossRef\]](#)
27. Raman B, Raman R, Rubin GD, Napel S. Automated tracing of the adventitial contour of aortoiliac and peripheral arterial walls in CT angiography (CTA) to allow calculation of non-calcified plaque burden. *J Digit Imaging* 2011; 24: 1078–1086. [\[CrossRef\]](#)
28. Carden DL, Granger DN. Pathophysiology of ischaemia-reperfusion injury. *J Pathol* 2000; 190:255–266. [\[CrossRef\]](#)
29. Granger DN. Ischemia-reperfusion: mechanisms of microvascular dysfunction and the influence of risk factors for cardiovascular disease. *Microcirculation* 1999; 6:167–178. [\[CrossRef\]](#)
30. Rogers JH, Laird JR. Overview of new technologies for lower extremity revascularization. *Circulation* 2007; 116:2072–2085. [\[CrossRef\]](#)
31. Kudo T, Chandra FA, Ahn SS. The effectiveness of percutaneous transluminal angioplasty for the treatment of critical limb ischemia: a 10-year experience. *J Vasc Surg* 2005; 41:423–433. [\[CrossRef\]](#)
32. Beard JD. Which is the best revascularization for critical limb ischemia: endovascular or open surgery? *J Vasc Surg* 2008; 48:11–16. [\[CrossRef\]](#)
33. Adam DJ, Beard JD, Cleveland T, et al. Bypass versus angioplasty in severe ischaemia of the leg (BASIL): multicentre, randomised controlled trial. *Lancet* 2005; 366:1925–1934. [\[CrossRef\]](#)
34. Conte MS, Bandyk DF, Clowes AW, et al. Results of PREVENT III: a multicenter, randomized trial of edifoligide for the prevention of vein graft failure in lower extremity bypass surgery. *J Vasc Surg* 2006; 43:742–751. [\[CrossRef\]](#)
35. Schanzer A. Impact of comorbidities on decision-making in chronic critical limb ischemia. *Semin Vasc Surg* 2009; 22:209–215. [\[CrossRef\]](#)
36. Arvela E, Soderstrom M, Korhonen M, et al. Finnvasc score and modified Prevent III score predict long-term outcome after infrainguinal surgical and endovascular revascularization for critical limb ischemia. *J Vasc Surg* 2010; 52:1218–1225. [\[CrossRef\]](#)
37. Stoner MC, Defreitas DJ, Manwaring MM, et al. Cost per day of patency: understanding the impact of patency and reintervention in a sustainable model of healthcare. *J Vasc Surg* 2008; 48:1489–1496. [\[CrossRef\]](#)
38. Feiring AJ, Krahn M, Nelson L, Wesolowski A, Eastwood D, Szabo A. Preventing leg amputations in critical limb ischemia with below-the-knee drug-eluting stents: the PaRADISE (PREventing Amputations using Drug eluting StEnts) trial. *J Am Coll Cardiol* 2010; 55:1580–1589. [\[CrossRef\]](#)
39. Kashyap VS, Pavkov ML, Bena JF, et al. The management of severe aortoiliac occlusive disease: endovascular therapy rivals open reconstruction. *J Vasc Surg* 2008; 48:1451–1457. [\[CrossRef\]](#)
40. Kedora J, Hohmann S, Garrett W, et al. Randomized comparison of percutaneous Viabahn stent grafts vs. prosthetic femoral-popliteal bypass in the treatment of superficial femoral arterial occlusive disease. *J Vasc Surg* 2007; 45:10–16. [\[CrossRef\]](#)
41. Conrad MF, Crawford RS, Hackney LA, et al. Endovascular management of patients with critical limb ischemia. *J Vasc Surg* 2011; 53:1020–1025. [\[CrossRef\]](#)
42. Karnabatidis D, Spiliopoulos S, Pastromas G, Katsanos K, Siablis D. Endovascular management of the arteria profunda femoralis: long-term angiographic and clinical outcomes. *Cardiovasc Intervent Radiol* 2012; 35:1016–1022. [\[CrossRef\]](#)
43. Odink H, van den Berg A, Winkens B. Technical and clinical long-term results of infrapopliteal percutaneous transluminal angioplasty for critical limb ischemia. *Vasc Interv Radiol* 2012; 23:461–467. [\[CrossRef\]](#)
44. Romiti M, Albers M, Brochado-Neto FC, et al. Meta-analysis of infrapopliteal angioplasty for chronic critical limb ischemia. *J Vasc Surg* 2008; 47:975–981. [\[CrossRef\]](#)
45. Lyden SP, Smouse HB. TASC II and the endovascular management of infrainguinal disease. *J Endovasc Ther* 2009; 16:5–18. [\[CrossRef\]](#)
46. Kudo T, Chandra FA, Kwun WH, Haas BT, Ahn SS. Changing pattern of surgical revascularization for critical limb ischemia over 12 years: endovascular vs. open bypass surgery. *J Vasc Surg* 2006; 44:304–313. [\[CrossRef\]](#)
47. Koppensteiner R, Spring S, Amann-Vesti BR, et al. Low-molecular-weight heparin for prevention of restenosis after femoropopliteal percutaneous transluminal angioplasty: a randomized controlled trial. *J Vasc Surg* 2006; 44:1247–1253. [\[CrossRef\]](#)
48. Arvela E, Dick F. Surveillance after distal revascularization for critical limb ischaemia. *Scand J Surg* 2012; 101:119–124.
49. Dorffler-Melly J, Koopman MM, Prins MH, Buller HR. Antiplatelet and anticoagulant drugs for prevention of restenosis/reocclusion following peripheral endovascular treatment. *Cochrane Database Syst Rev* 2005; 1:CD002071.
50. Alonso-Coello P, Bellmunt S, McGorrian C, et al. Antithrombotic therapy in peripheral artery disease: Antithrombotic Therapy and Prevention of Thrombosis, 9th ed: American College of Chest Physicians Evidence-Based Clinical Practice Guidelines. *Chest* 2012; 141:669–690.
51. Visona A, Tonello D, Zalunardo B, et al. Antithrombotic treatment before and after peripheral artery percutaneous angioplasty. *Blood Transfus* 2009; 7:18–23.
52. Efficacy of oral anticoagulants compared with aspirin after infrainguinal bypass surgery (The Dutch Bypass Oral Anticoagulants or Aspirin Study): a randomised trial. *Lancet* 2000; 355:346–351. [\[CrossRef\]](#)
53. Feiring AJ, Wesolowski AA, Lade S. Primary stent-supported angioplasty for treatment of below-knee critical limb ischemia and severe claudication. *J Am Coll Cardiol* 2004; 44:2307–2314. [\[CrossRef\]](#)
54. Iida O, Uematsu M, Soga Y, et al. Impact of angiosome in endovascular therapy on the limb salvage for the patients with critical limb ischemia presenting with isolated infrapopliteal lesions. *J Am Coll Cardiol* 2011; 57:1667–1667. [\[CrossRef\]](#)
55. Taylor GI, Palmer JH. 'Angiosome theory'. *Br J Plast Surg* 1992; 45:327–328. [\[CrossRef\]](#)
56. Taylor GI, Pan WR. Angiosomes of the leg: anatomic study and clinical implications. *Plast Reconstr Surg* 1998; 102:599–616. [\[CrossRef\]](#)
57. Baumann F, Willenberg T, Do D-D, et al. Endovascular revascularization of below-the-knee arteries: prospective short-term angiographic and clinical follow-up. *J Vasc Interv Radiol* 2011; 22:1665–1673. [\[CrossRef\]](#)
58. Shrikhande GV, Khan SZ, Hussain HG, et al. Lesion types and device characteristics that predict distal embolization during percutaneous lower extremity interventions. *J Vasc Surg* 2011; 53:347–352. [\[CrossRef\]](#)
59. Rossi M, Carpi A. Skin microcirculation in peripheral arterial obliterative disease. *Biomed Pharmacother* 2004; 58:427–431. [\[CrossRef\]](#)
60. Brevetti G, Corrado S, Martone VD, et al. Microcirculation and tissue metabolism in peripheral arterial disease. *Clin Hemorheol Microcirc* 1999; 21:245–254.