

Secondary interventions following endovascular repair of abdominal aortic aneurysm

Krishnan Subramanian, Kenneth R. Woodburn, Simon J. Travis, John Hancock

PURPOSE

To review the outcomes of endovascular abdominal aortic aneurysm repair (EVAR) procedures, to determine the incidence of adverse events, and to assess the need for secondary radiological/surgical interventions.

MATERIALS AND METHODS

Data from 57 consecutive patients entered in a prospective EVAR database were studied. In addition to database interrogation, case notes and radiology records were reviewed. Frequency and outcome of complications were evaluated after stent-graft placement (mean follow up 20 months).

RESULTS

Overall, 24 adverse events were recorded in 57 patients (42%). The events were endoleaks (14/24), stent migrations (3/24), deployment problems (2/24), limb occlusions (2/24), limb kink (1/24), and femoro-femoral crossover occlusions (2/24). Of all the endovascular patients studied, 23% (13/57) required secondary interventions to maintain aneurysm exclusion. The mean time to secondary intervention in this series was 14 months.

CONCLUSION

Over 40% of EVAR procedures were associated with suboptimal clinical outcomes, and more than 20% of the patients required secondary interventions within 5 years of surgery. This high incidence of late secondary intervention is a cause for concern and emphasizes the need for lifelong follow-up.

Key words: • endoleak • aortouni-iliac • femoro-femoral crossover • aortobi-iliac • endograft

The natural history of abdominal aortic aneurysm (AAA) is enlargement and rupture (1). The prevalence of AAA has increased in the past 30 years (2), and up to 50% of patients with untreated aneurysms will die of rupture within a 5-year period (3-5). Open surgical repair is effective in the prevention of rupture and can be performed with mortality rates as low as 2%-5% (6-9). However, open surgical repair is associated with significant morbidity in 15%-30% of patients (9, 10).

Endovascular repair of AAA has been reported to reduce the rate of 30-day mortality following elective aneurysm repair. In the endovascular abdominal aortic aneurysm repair (EVAR) group of a previous study, 30-day mortality was 1.7% versus 4.7% in the open repair group (11). Since the first endovascular aneurysm exclusion by Parodi et al. in 1991 (12), a number of devices and strategies have been evaluated (13-20). Successful aneurysm exclusion has been achieved in 50%-90% of cases, (13-20), but a number of problems have been identified, including vessel perforation, inability to completely exclude the aneurysm resulting in endoleaks, limb kinks, and device occlusion. For this reason, lifelong follow-up is recommended to identify those at risk. Continued or recurrent growth of the aneurysm, with or without endoleaks, and device migration are associated with an increased risk of rupture (21, 22). An Ad Hoc Committee for Standardised Reporting Practices in Vascular Surgery of the Society for Vascular Surgery/American Association for Vascular Surgery, reported an annual rupture rate of 1% following EVAR (22). Rupture may be prevented by prophylactic secondary interventions during follow-up. This constitutes an additional burden for the patient, as well as for health care resources (23). Thus, the need for secondary interventions is an important indicator of the intermediate and long-term success of EVAR.

In this report, we analyse the various complications arising post EVAR and the need for secondary interventions and their outcomes in a single District General Hospital, which began endovascular AAA repairs in 1998.

Materials and methods

Baseline data on suitable patients were recorded in a standard fashion for submission to either the vascular society's Registry of Endovascular Treatments for Aortic Aneurysm (RETA database), or to the United Kingdom EVAR trial, which our institution contributes to. Following EVAR, patient follow-up by clinical examination and computed tomography (CT) was undertaken at 3, 6, 9, and 12 months post-operatively, and yearly thereafter. A total of 57 procedures were undertaken between 1998 and 2004, of which 53 were elective cases. Four patients underwent EVAR for an acutely symptomatic or ruptured AAA. Of the 57 procedures, 43 had bifurcated grafts and 14 underwent aortouni-iliac grafting (Table 1) in conjunction with femoro-femoral crossover grafts (Gelsoft, Vascutek, Inchinnan, UK).

From Peninsula Medical School and Vascular Surgery Unit (K.R.W. ✉ ken.woodburn@medix-uk.com), Royal Cornwall Hospital, Truro, Cornwall, UK.

Received 24 November 2005; revision requested 1 March 2006; revision received 25 March 2006; accepted 2 April 2006.

Table 1. Types of grafts.

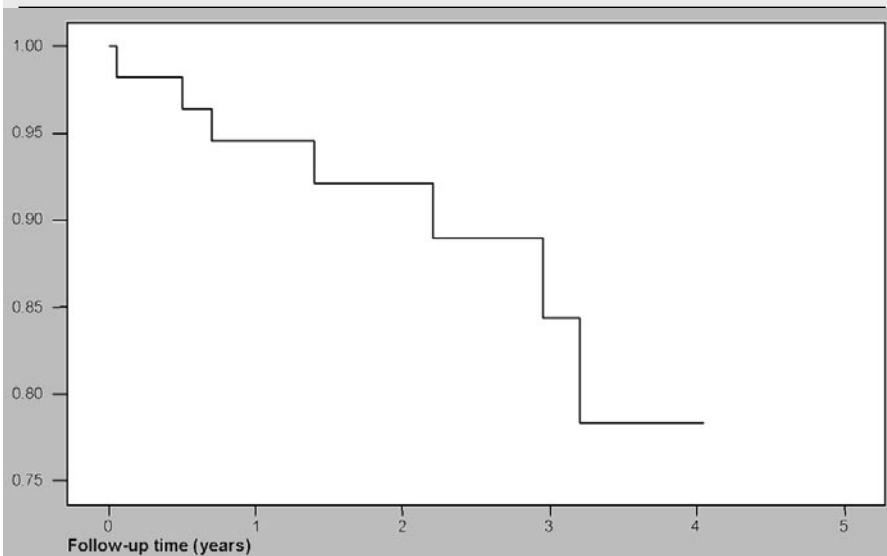
	Bifurcate	Uni-iliac	Total
Cook Zenith®	33	9	42
AneuRx®	6	4	10
EVT®	1	2	3
Bard Endologix®	1	0	1
Vanguard®	1	0	1

Table 2a. Number of complications and their distribution.

	Total n=24	%
Endoleaks	14	58
Deployment	2	8
Stent migration	3	12.5
Limb occlusion	2	8
Limb kink	1	4
Femoro-femoral crossover	2	8

Table 2b. Complications that needed definitive secondary intervention in the study group and their break-down.

Procedure	Number (13)	
Type I endoleak	3	1-multiple procedure
Type II endoleak	4	2-multiple procedures
Graft migration and kinks	3	
Type III endoleak	1	
Femoro-femoral crossover	2	1-needed two revisions

Table 3. Follow-up time following endovascular aneurysm repair.

During the study period, 54 males and 3 females underwent EVAR. The mean age of the patients was 73 years (range: 53-90 years). The median size of the aneurysms was 57 mm (range: 45-89 mm). Patients with aneurysms smaller than 55 mm had to undergo the procedure, as they were symptomatic.

Outcome events and associated variables

All secondary interventions that occurred after the primary procedure were included in the analyses. Pre-operative embolisations of the internal iliac and/or inferior mesenteric arteries (n = 14 cases) were not considered to be secondary interventions. However, any post-EVAR complications or reinterventions were included, regardless of the length of time that elapsed since the initial procedure. The complications noted at the time of deployment were not included as secondary interventions. In patients who underwent multiple procedures, each procedure was considered

a follow-up of a single secondary intervention. Details of the complications noted in the study group, their distribution, and indications for secondary interventions are categorised and shown in Tables 2a and 2b.

Definition and statistical analysis

Outcome measures included perioperative mortality, defined as death within 30 days after the operation or any death occurring during the same hospitalisation, aneurysm rupture, and aneurysm-related mortality, defined as any death occurring within 30 days after the primary or secondary aneurysm-related treatment, or any aneurysm-related death anytime after treatment (24, 25).

Secondary outcome measures included perioperative major morbidity, defined as any major complication occurring within 30 days of the operation, and need for secondary procedures, defined as any percutaneous or open surgical procedure. Rate of survival in years from the time of the primary procedure was estimated with the Kaplan-Meier method (Table 3). All statistical analyses were conducted with SPSS software.

Results

The mean follow-up for the entire study population of 57 patients was 20 months (range: 3-42 months). Among the study population, 13 patients (23%) required secondary interventions at a mean of 14 months following the initial endograft procedure. Although 24 patients (42%) were considered to have had a sub optimal outcome, 11 of the patients did not require secondary interventions since the perceived problems either resolved spontaneously or remained under follow-up (Table 2b). Six patients who underwent EVAR during the study period died from malignant disease, MI, and other causes (Table 4). In addition, 1 patient died of a ruptured AAA following EVAR.

Table 4. Cause of death in our series.

Cause	#
Myocardial infarction	2
Cancer	2
Pulmonary infection	1
EVAR-related	1

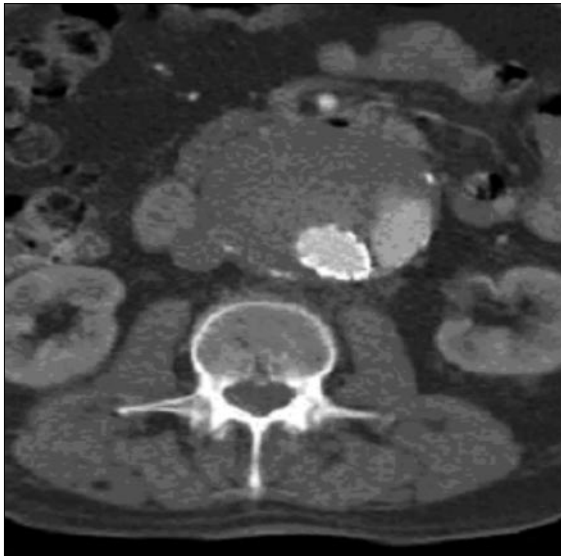

Figure 1. CT showing Type I endoleak.

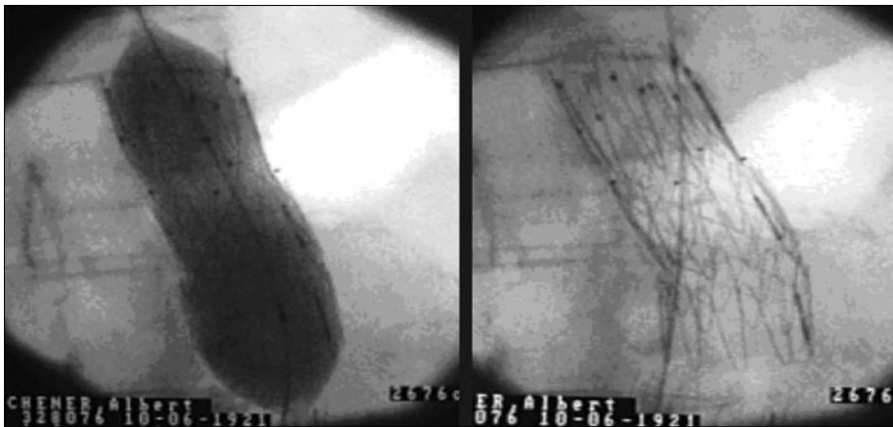


Figure 2. Upper-end leak (Type I endoleak) correction with extension graft (Palmaz® stent).

In this series, there were no conversions to open repair at the time of initial deployment, although 1 mini-laparotomy-assisted deployment was required to enable the deployment of a second bifurcated endovascular device following distal displacement of the original device, which ended up lodged at the aortic bifurcation at the time of deployment. One other case suffered from external iliac artery dissection at the time of deployment. These were the only two complications encountered at the time of deployment.

Type I endoleaks

Of the 14 cases of endoleaks, 3 were of the type I variety, 2 from the upper attachment site and 1 from the lower end. The upper end type I endoleaks were further managed by deploying Palmaz stents to stabilize the neck, correct excessive angulation, and achieve a seal, thus correcting the endoleak

(Figures 1 and 2). The Ad Hoc Committee for Standardised Reporting Practices in Vascular Surgery of the Society for Vascular Surgery/American Association for Vascular Surgery e-distal type I endoleak arose around a common iliac occluder deployed at time of aortouni-iliac EVAR. This required open ligation of the common iliac artery and percutaneous coil embolization of both the residual common iliac artery and lumbar collaterals to finally eliminate the endoleak.

Type II endoleaks

Ten cases of type II endoleaks were noted in our study, of which 4 were from lumbar vessels, 2 were from the inferior mesenteric artery, and 4 others were from both IMA and lumbar vessels (Type IIb); 3 resolved without treatment, 3 underwent successful coil embolization of the feeding vessels, and 1 involving both IMA and lumbar ves-

sels ultimately underwent emergency open ligation of lumbar vessels when presenting acutely with a presumed leak on CT scan, although no blood was observed with the aneurysm sac during the operation. This patient had undergone multiple attempts to treat the endoleak, including 2 attempts at coil embolization of the IMA and lumbar, and another attempt through CT guided thrombin injection into the sac (Figures 3 and 4). All our patients who had their endoleaks embolized had either a persistent leak for more than 10 months at follow-up, or showed no decrease in post procedure sac diameter, with persisting endoleaks.

The other 3 cases remained under observation with persisting endoleaks, 2 of which showed no increase in sac size, while the 3rd endoleak was expected to resolve spontaneously.

Type III endoleak

One case of type III endoleak resulted from distraction of the iliac limb from the main graft, which was treated with iliac limb extension to bridge the defect and eliminate the endoleak. (Figures 5 and 6)

Graft migration

Three cases of significant upper end graft migration (3 out of the 10 AneuRx® devices implanted) were noted in our series, of which 1 was being follow-up and 2 underwent interventions. The first case was treated by deployment of a Cook® cuff at the top end of the displaced device; however, this patient died 2 months later and post-mortem showed a large intraperitoneal bleed, presumably as a result of further displacement of the AneuRx® device, with subsequent AAA rupture.

In the second case a new Cook AUI® device was deployed within the original displaced AneuRx® device to effectively redo the procedure with a good result to date.

Limb kinks/occlusion

There were 2 iliac limb occlusions noted in bifurcated devices (4.6% of all bifurcates), 1 of which was treated with a femoro-femoral crossover graft, the remaining patient, although suffering from gluteal claudication, declined further intervention and ultimately died of a myocardial infarction some months later.

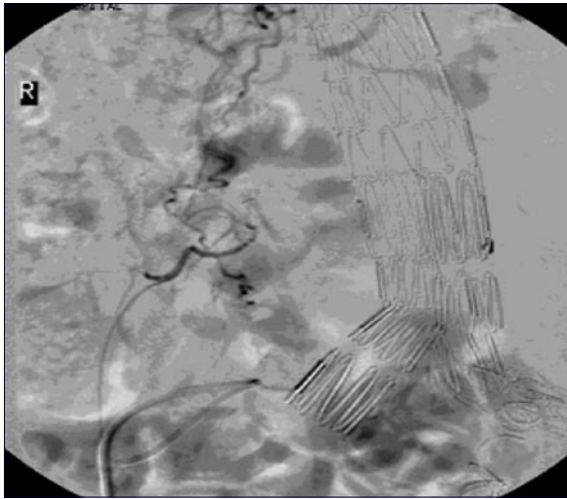


Figure 3. Coil embolization of feeding lumbar vessel in a case of persistent type II endoleak.

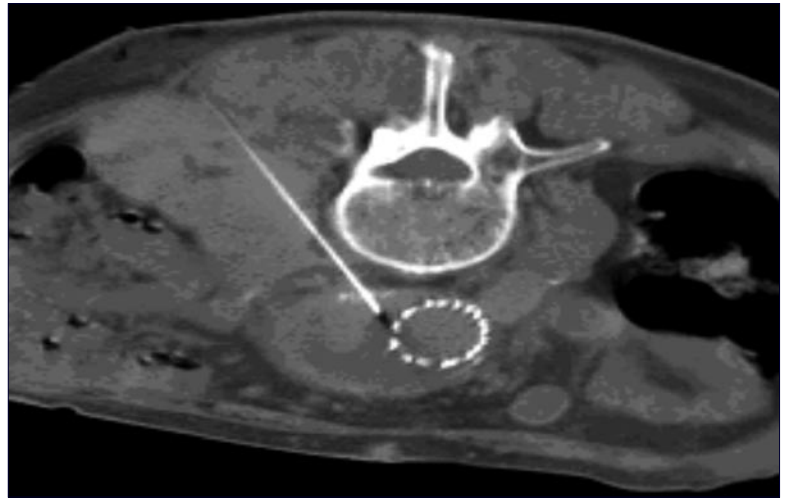


Figure 4. CT guided direct intra-sac injection of thrombin in a case of type II endoleak persisting after coil embolization of feeding lumbar vessels.

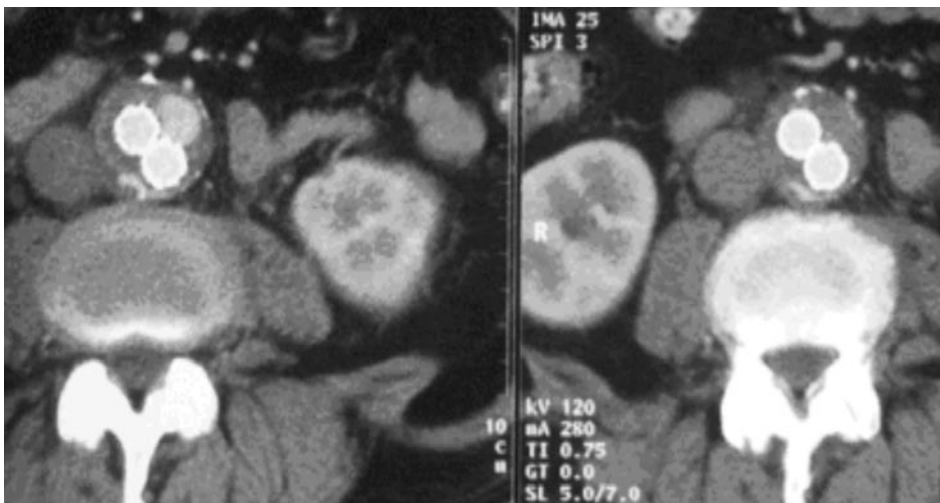


Figure 5. Type III endoleak from distraction of iliac limb from the main graft.

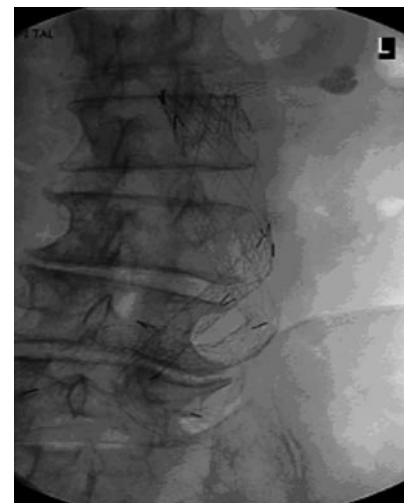

Figure 6. Correction of type III endoleak with iliac limb extension graft.

One case of aortouni-iliac main limb kink (40% kink) was noted and to date, this patient has remained under observation.

In 14 patients who had aortouni-iliac stent grafts and femoro-femoral crossover, there was 1 case of infection necessitating replacement of the crossover component. This new graft reoccluded during the follow-up. There was 1 additional occlusion of a femoro-femoral crossover graft that as of this writing is awaiting reconstruction.

Thus far, only 1 death has been attributed to a ruptured AAA following EVAR, though 6 other patients have been lost in follow-up from deaths due to cancer, myocardial infarction and other causes.

Discussion

Following the introduction of EVAR over a decade ago, application of this technique has developed rapidly. During this period, both the endovascular devices available and the technique have been improved, but some questions concerning EVAR are still unanswered. Most investigators have shown that EVAR is a feasible procedure in a selected group of patients with good short-term results (24), and the recent EVAR trial 30-day results have confirmed this. In 2000, the EUROSTAR collaborators reported a cumulative risk of rupture following endograft placement of approximately 1% per year (22). Yet, a 2004 update of the EUROSTAR data, with withdrawn devices excluded, revealed a cumulative annual rupture rate of only 0.4%, which

is encouraging, as second-generation devices are vastly improved (26).

In our series, there was no early mortality (<30 days) and no conversion to open repair. Cupers et al. (21), in an analysis of the risk of conversion, observed that primary and first month conversions were most often related to problems of access and migration of the device. The secondary intervention rate of 23% observed in our series is comparable to other series (11, 27, 28). The initial cause of open conversion due to device deployment failure and device migration has been reduced, to a certain degree, with the new generation of devices and improved patient selection.

In the present study, the most common indication for secondary intervention was type II endoleak, as most

of the devices used in our centre were of the second-generation (46/57), and this is found to be the case in all other centres using the new generation of devices (29). Although several series have placed the incidence of postoperative endoleak between 10% and 50% (30-32), the clinical significance of these early endoleaks is not clear. Over 50% of initially-identified endoleaks seal spontaneously, and the subsequent clinical course of patients with sealed endoleaks does not differ from patients who never had one documented (33, 34). Endoleak onset is highly variable and unpredictable. Conventional wisdom currently dictates that type II endoleaks, in particular, do not justify conversion, unless there is also evidence of continuing expansion of the aneurysm sac. Recognition of the importance of endotension has convinced many physicians that continuing or renewed expansion of the aneurysm mandates conversion, regardless of the presence or absence of a detectable endoleak. (22).

The most common cause of late secondary intervention was endoleak in the new generation of devices, and migration was the prime indication in half of all secondary interventions with older generation of devices (29). Endoleaks, both type I and type II, were the most frequent indication for late secondary intervention. Type I or attachment site endoleaks at the upper end may be due to under sizing or inadequate fixation of the stent graft (early type I), and alternatively, late dilatation of the infra renal neck may occur with similar effects (late type I) (35, 36, 37, 38).

Since the inception of EVAR, there has been controversy about the management of a patent lumbar and IMA arising from the sac. Over sewing of these vessels is an integral part of conventional open surgery for this condition. Although type II endoleaks due to perfusion of the sac from these vessels are seen in 20% to 30% of patients, it is thought that one-half of early leaks seal spontaneously within several months of follow-up. But endoleaks may persist in 10% to 15% of patients, and late endoleaks may develop in another 5% to 10% of patients (39).

Still, much controversy and debate surround over diagnosis, observation, and management of type II endoleaks,

and a definite solution has not been found. Controversy also surrounds the timing of intervention and the best method of excluding the sac from circulation, either by coil embolization, which at present is the preferred method, but long-term follow-up results are not encouraging; there is a 60% failure rate for type II endoleak coil embolizations, as reported by Solis et al. (40). The other common method being used involves thrombogenic materials to occlude or inject directly into the sac (41), or a combination of both thrombogenic material and coils (26), and less commonly, open surgical ligation to laparoscopic clipping.

Secondary femoro-femoral crossover bypass was always undertaken for aortouni-iliac grafts, and these femoro-femoral crossover grafts are prone to occlusion, kinks, and infection. Yilmaz et al. in their series of 148 patients with cross femoral bypass grafting (CFBG) in aortomoniliac endovascular aortic aneurysm repair that were followed-up for 38 months, showed a complication rate of 5.4%, and when complication did occur (infection, thrombosis, kinking, and distal stenosis) the consequences were dire, as 50% of the patients (4/8) with CFBG-related complications died (42). Late graft limb stenosis/thrombosis may be due to increased angulations and kinking, secondary to distortion of the device. This is caused by shrinkage of the excluded aneurysm in transverse and longitudinal directions. (43) In our series, this was observed to be less, probably requiring additional follow-up to note such incidence.

Despite the high incidence of complications and secondary interventions in this series, most of the secondary interventions were managed percutaneously. Transfemoral procedures constituted the most frequent category of secondary interventions. In the majority, these procedures consisted of aortic or iliac limb extension for migration or embolization of an endoleak. All abnormal findings on follow-up imaging were investigated, including endoleaks of all types, thrombosis, stenosis, and kinking of the end graft, which were seen significantly more frequently in patients with late endovascular procedures. This emphasises the importance of a previous observation by Holzeinbein et al. (28), that most late adverse events can be

resolved with appropriate endovascular techniques. The same authors pointed out that these secondary interventions are associated with low morbidity and mortality rates when compared to open procedures.

An analysis of our series demonstrated a primary success rate for AAA exclusion by endovascular means of 78%, which rose to about 90% after successful secondary interventions.

Although 42% developed adverse events during follow-up, only 23% had secondary interventions. This is comparable with other reports and includes 5 cases (9%) requiring operative interventions (EUROSTAR 18%). Three patients had more than one secondary intervention and 1 death was directly attributed due to complications of EVAR. These findings have considerable implications. First, patients need to be informed about the risk of complications that may necessitate a secondary intervention. Second, secondary interventions reduce the overall cost-effectiveness of the procedure. Finally, overall, secondary interventions were associated with a slightly higher probability of morbidity in the years following the primary procedure. This may probably be due to the advanced age of the study group patients, such that any additional interventions were fraught with the risk of morbidity. Lifelong patient follow-up with accurate imaging techniques is, therefore, essential following EVAR.

Conclusion

The presented series represents the entire experience of one district general hospital, and the high incidence of complications could have been related to the learning curve and the use of both first and second-generation devices. Still, over 40% of EVAR procedures were associated with a sub optimal clinical outcome and more than 20% of the patients required secondary interventions within 5 years of initial surgery. This high incidence of late secondary intervention is a cause for concern and emphasises the need for lifelong patient follow-up. These results are comparable to most other centres and centre-oriented results should be analysed even though overall EVAR trials are currently being concluded.

References

- Ernst CB. Abdominal aortic aneurysm. *N Engl J Med* 1993; 328:1167-1172.
- Bengtsson J, Bergqvist D, Sternby NH. Increasing prevalence of abdominal aortic aneurysm: a necropsy study. *Eur J Surg* 1992; 58:11-23.
- Ouriel K, Green RM, Donayre C, et al. An evaluation of new methods of expressing aortic aneurysm: relationship to rupture. *J Vasc Surg* 1992; 15:12-20.
- Johanansson G, Nyaahl S, Oloffson P, et al. Survival of patients with abdominal aortic aneurysms: comparison between operative and non-operative management. *Eur J Vasc Surg* 1990; 4:497-502.
- Nevitt MP, Ballard DJ, Hallet JW. Prognosis of abdominal aortic aneurysms; a population-based study. *N Engl J Med* 1989; 321:1009-1014.
- Reigel MM, Hollier LH, Kazmier FJ, et al. Late survival in abdominal aortic aneurysm patients: the role of selective myocardial revascularization on the basis of clinical symptoms. *J Vasc Surg* 1987; 5:222-228.
- Bernstein EF, Dillely RB, Randolph HF, et al. The improving long term outlook for patients: the role of selective myocardial revascularisation on the basis of clinical symptoms. *J Vasc Surg* 1988; 207:318-322.
- Golden MA, Whittmore AD, Donaldson MC, Mannic JA. Selective evaluation and management of coronary artery disease in patients undergoing repair of abdominal aortic aneurysm. A 16 year experience. *Ann Surg* 1990; 212:415-423.
- Cambria RP, Brewster DC, Abbott WM, et al. The impact of selective use of dipyridamole - thallium scans and surgical factors on the current morbidity of aortic surgery. *J Vasc Surg* 1992; 15:43-50.
- Johnston KW. Multicenter prospective study of non-ruptured abdominal aortic aneurysm Part 2. Variables predicting morbidity and mortality. *J Vasc Surg* 1989; 9:437-447.
- Greenhalgh RM, Brown LC, Kwong GP, Powell JT, Thompson SG. Comparison of endovascular aneurysm repair with open repair in patients with abdominal aortic aneurysm (EVAR trial 1), 30-day operative mortality results: randomised control trial. *Lancet* 2004; 364:843-848.
- Parodi JC, Palmaz JC, Barone HD. Transfemoral intraluminal graft implantation for abdominal aortic aneurysm. *Ann Vasc Surg* 1991; 5:491-499.
- Moore WS, Rutherford RB. Transfemoral endovascular repair of abdominal aortic aneurysm; results of the North American EVT phase 1 trial. *J Vasc Surg* 1996; 23:543-553.
- White GH, Yu W, May J, et al. Three year experience with the White-Yu Endovascular GAD Graft for transluminal repair of aortic and iliac aneurysms. *J Endovasc Surg* 1997; 4:124-136.
- Blum U, Langer M, Spillner G, et al. Abdominal aortic aneurysms; preliminary technical and clinical results with transfemoral placement of endovascular self-expanding stent grafts. *Radiology* 1996; 198:25-31.
- May J, White GH, Yu W, et al. Surgical management of complication following endoluminal grafting of abdominal aortic aneurysms. *Eur J Vasc Endovasc Surg* 1995; 10:51-59.
- Chuter TAM, Wendt G, Hopkinson BR, et al. Transfemoral insertion of a bifurcated endovascular graft for aortic aneurysm repair: the first 22 patients *Cardiovasc Surg* 1995; 3:121-128.
- Mialhe C, Amicable C, Becquemin JP. Endovascular treatment of infrarenal abdominal aneurysms by the Stentor system; preliminary results of 79 cases. *J Vasc Surg* 1997; 26:199-209.
- Allen RC, Fogarty TJ. The Medtronic - Aneurx modular bifurcated graft. In: Yao JST, Pearce WH, eds. *Techniques in vascular and endovascular surgery*. Appleton and Lange, 1998; 401-409.
- White RA, Donayre CE, Walot I, et al. Modular bifurcation endoprosthesis for treatment of abdominal aortic aneurysm. *Ann Surg* 1997; 226:381-389.
- Cuyppers P, Buth J, Harris PL, Gevers E, Lahey R. Realistic expectations for patients with stent-graft treatment of abdominal aortic aneurysms. Results of a European multicentre registry. *Eur J Vasc Endovasc Surg* 1999; 17:507-516.
- Harris PL, Vallabhaneni SR, Pascal D, et al. Incidence and risk factors of late rupture conversion and death after EVAR of infrarenal abdominal aortic aneurysm. *J Vasc Surg* 2000; 739-746.
- White G. Ad Hoc Committee for standardised reporting practices in vascular surgery of the society for Vascular Surgery/American Association for Vascular Surgery. *Proceedings IES*. Sidney, Australia, 1998.
- Arko FR, Lee A, Hill BB, et al. Aneurysm-related death: primary end point analysis for comparison of open and endovascular repair. *J Vasc Surg* 2002; 36:297-304.
- Chaikof EL, Bernahrd VM, Blankensteijn JD, Harris PL, White GH, et al. Reporting standards for endovascular aortic aneurysm repair. *J Vasc Surg* 2002; 35:1048-1060.
- Van Marrewijk CJ, Fransen G, Laheij JF, et al. Is a type 1 endoleak after EVAR a harbinger of risk? Causes and outcome of open conversion and aneurysm follow up. *Eur J Vasc Endovasc Surg* 2004; 27:128-137.
- Blum U, Voshage G, Beyersdorf F et al. Two centre German experience with a system for bifurcated stent graft insertion; *J Endovasc Surg* 1997; 4:13-22.
- Holzenbein TJ, Kretschmer G, Thurner S, et al. Mid term durability abdominal aortic aneurysm repair: a word of caution. *J Vasc Surg* 2001; 33:46-54.
- Torello F. Effect of improved endograft design on outcome of endovascular aneurysm repair. *J Vasc Surg* 2004; 40:216-221.
- Wever JJ, Blankensteijn JD, Broeders IAMJ, Eikelboom BC. Length measurements of the aorta after endovascular abdominal aneurysm repair. *Eur J Vasc Endovasc Surg* 1999; 18:481-486.
- Moore WS, Rutherford RB. Transfemoral endovascular repair of abdominal aortic aneurysm: results of the North American EVT phase 1 trial. *EVT investigators. J Vasc Surg* 1996; 23:543-553.
- White GH, Yu W, May J, Charfour X, Stephen MS. Clinical consequence of periprosthetic leak after endovascular repair of abdominal aortic aneurysm. *Endovascular technologies investigators. J Vasc Surg* 1998; 27:606-613.
- Maourou M, Zajko A, Sugimoto H, Estandari M, Webste M. Fate of endoleaks after endoluminal repair of abdominal aortic aneurysm with the EVT device. *Eur J Endovasc Surg* 1998; 18:185-190.
- Resch T, Ivancev K, Lindh M, et al. Persistent collateral perfusion of abdominal aortic aneurysm after endovascular repair does not lead to progressive change in aneurysm diameter. *J Vasc Surg* 2000; 31:599-606.
- Zarins CK, White RA, Fogarty TJ. Aneurysm rupture after endovascular repair using the Aneurx stent graft. *J Vasc Surg* 2000; 31:960-970.
- Politz JK, Newman VS, Stewart MT. Late abdominal aortic aneurysm rupture after Aneurx repair: a report of three cases. *J Vasc Surg* 2000; 31:599-606.
- Saghal A, Veith FJ, Lipitz E, et al. Diameter changes in isolated iliac artery aneurysms 1 to 6 years after endovascular graft repair. *J Vasc Surg* 2000; 33:289-295.
- Chuter TA, Risberg B, Hopkinson BR, et al. Clinical experience with a bifurcated endovascular graft for abdominal aortic aneurysm repair. *J Vasc Surg* 1996; 24:152-168.
- Baumveith FJ, Mohan Adisesiah, Chuter M, et al. Nature and significance of endoleaks and endotension: summary of opinions expressed at an international conference. *J Vasc Surg* 2002; 35:1029-1035.
- Solis M, Ayerdi J, Babcock GA, et al. Mechanism of failure in the treatment o type 2 endoleak with percutaneous coil embolisation. *J Vasc Surg* 2002; 36:485-491.
- Harris P, Brennan J, Martin J, et al. Longitudinal aneurysm shrinkage following endovascular aortic aneurysm repair: a source of intermediate and late complications. *J Endovasc Surg* 1999; 6:11-16.
- Yilmaz LP, Abraham CZ, Reilly LM, et al. Is cross-femoral bypass grafting a disadvantage of aortomoniliac endovascular aortic aneurysm repair? *J Vasc Surg* 2003; 38: 753-757.
- Buth J, Lheij RJJ. Early complications and endoleaks after endovascular abdominal aortic aneurysm repair; report of a multicenter study. *J Vasc Surg* 2000; 31:134-146.