

Endovascular treatment of peripheral vascular lesions with stent-grafts

Baran Önal, Erhan T. Ilgıt, Şule Koşar, Koray Akkan, Terman Gümüş, Sergin Akpek

PURPOSE

To evaluate our results of stent-graft implantation for the endovascular treatment of peripheral vascular lesions.

MATERIALS AND METHODS

Seventeen patients underwent repair of iatrogenic, traumatic, or spontaneous vascular lesions by means of endovascular stent-grafts. The study cases consisted of 10 cardiac catheterization-induced femoral arteriovenous fistulas (AVFs) located between the deep femoral artery and the femoral vein, one iatrogenic AVF between the common iliac artery and vein, one penetrating trauma-induced AVF between the superficial femoral artery and vein, two penetrating trauma-induced pseudoaneurysms in the axillary and popliteal arteries, and three spontaneous or atherosclerosis-related iliac artery aneurysms. Balloon-expandable or self-expandable stent-grafts were used in all 17 cases.

RESULTS

All the stent-grafts were deployed successfully. In catheterization-induced femoral AVFs, complete closure of the fistulas was immediately accomplished in 9 of the 10 cases. Blood flow within the pseudoaneurysms of the axillary artery and the popliteal artery, and aneurysms of the iliac arteries were stopped. Partial closure was achieved in two patients with traumatic iliac and femoral AVFs. For the patients who reported subsided complaints, mean follow-up for 24 months with clinical examination and color Doppler ultrasound revealed patency of the stented segments.

CONCLUSION

Our results suggest that endovascular treatment of various types of peripheral vascular lesions with stent-grafts is a low-risk procedure, which appears to be less invasive than surgery.

Key words: • stents • aneurysm • pseudoaneurysm • arteriovenous fistula

The concept of a transluminally placed endovascular graft was initially proposed by Dotter in 1969 (1). Subsequently, Balko et al. (2) reported the transfemoral placement of an intraluminal polyurethane-coated prosthesis in a sheep abdominal aortic aneurysm (AAA) model. The first report of the use of this technique in man was by Parodi et al. (3). They reported the treatment of AAAs by transfemoral intraluminal Dacron grafts, anchored by modified stainless steel stents. Since then, endovascular stent-graft placement has been increasingly used to treat vascular lesions, mainly AAAs. There are also a number of reports on AAA treatment of iatrogenic or traumatic vascular lesions, namely pseudoaneurysms, arteriovenous fistulas (AVFs), arterial ruptures, and perforations (4-7).

Materials and methods

Between February 1998 and July 2004, 17 patients (10 men, 7 women; age range, 21-85 years; mean age, 61 years) underwent repair of peripheral vascular lesions by means of endovascular stent-grafts (Table). The patient population consisted of 10 cardiac catheterization-induced femoral AVFs, located between the deep femoral artery and the femoral vein, one penetrating trauma-induced AVF between the superficial femoral artery and vein, one lumbar discectomy-induced iatrogenic AVF between the common iliac artery and vein, one penetrating trauma-induced right axillary artery pseudoaneurysm, one penetrating trauma-induced left popliteal artery pseudoaneurysm, one spontaneous right iliac artery aneurysm, and two aneurysms associated with atherosclerotic obstructive disease in the iliac arteries.

Two types of endovascular stent-grafts were used: balloon expandable Jostent peripheral stent grafts (Jomed, Rangendingen, Germany) in 13 patients, and a self-expandable Wallgraft (Boston Scientific, San Francisco, CA, USA), Hemobahn (W. L. Gore Associates, Inc., Flagstaff, AZ, USA), or Stenford (Stenford Groupe Valendos S.A., Nanterre, France) stent-graft in four patients. The Jostent peripheral stent-graft is made using a sandwich technique, whereby the expandable polytetrafluoroethylene (PTFE) graft material is placed between two thin stents. The Wallgraft is a flexible self-expanding covered stent-graft made of a cobalt and titanium alloy, which is covered with polyethylene terephthalate (PET). The Hemobahn stent-graft consists of intranodal ultra-thin-wall PTFE graft material on the inner surface and a self-expanding nitinol stent on the exterior. The Stenford covered stent-graft is a self-expanding nitinol stent, which is covered with Dacron graft material.

Patients with suspected vascular lesions were referred to us for confirmation by color Doppler ultrasonography. The definitive diagnoses of the lesions were made by selective angiography. All procedures were performed in an angiography unit with roadmapping capacity (Advantx

From the Department of Radiology (B.Ö. ✉ baranonal@gazi.edu.tr), Gazi University Medical School, Ankara, Turkey.

Received 18 April 2005; revision requested 19 May 2005; revision received 25 May 2005; accepted 10 June 2005.

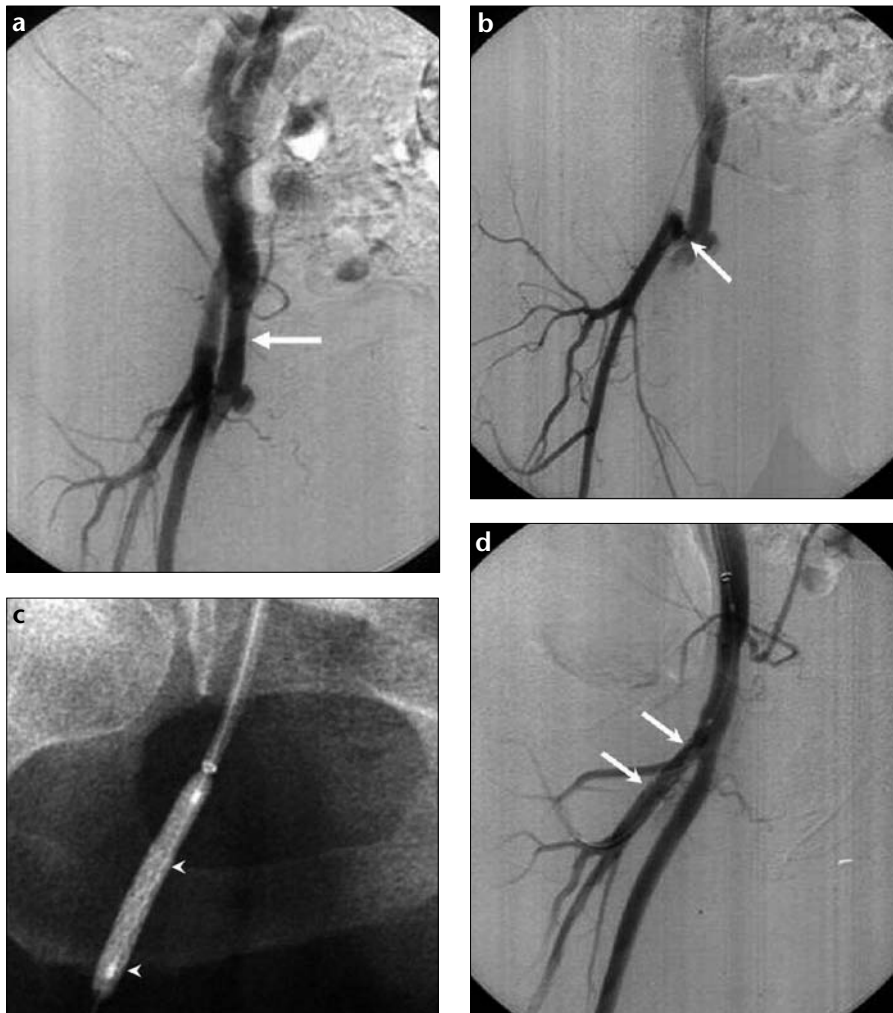


Figure 1. a-d. Cardiac catheterization-induced femoral AVF. **a.** Right iliofemoral angiogram shows an AVF originating around the femoral artery bifurcation. Note the immediate venous return to the femoral vein (arrow). **b.** Selective injection into the deep femoral artery reveals that the AVF is between the deep femoral artery and the femoral vein (arrow). **c.** Native X-ray shows the insertion of a stent-graft (arrowheads) (25 mm long, mounted on a 5.0 mm peripheral balloon) through a 7 Fr flexible guiding sheath by contralateral femoral approach. **d.** Angiogram after stent-graft (arrows) implantation shows the immediate closure of the fistula.

Table. Summary of cases

Patient No.	Age/Sex	Lesion type	Lesion location	Follow-up (months)
1	71, F	AVF	DFA- FV	43
2	67, F	AVF	DFA- FV	37
3	70, M	AVF	DFA- FV	22
4	61, M	AVF	DFA- FV	38
5	72, F	AVF	DFA- FV	41
6	65, F	AVF	DFA- FV	23
7	70, M	AVF	DFA- FV	22
8	63, F	AVF	DFA- FV	21
9	69, F	AVF	DFA- FV	20
10	62, M	AVF	DFA- FV	38
11	35, M	AVF	SFA/DFA-FV	12
12	38, M	AVF	CIA-V	1
13	21, F	PA	R axillary artery	50
14	85, M	PA	L popliteal artery	6
15	49, M	A/plaque	R iliac artery	28
16	58, M	A	L iliac artery	3
17	74, M	A/plaque	L iliac artery	8

F: female, M: male, AVF: arteriovenous fistula, DFA: deep femoral artery, SFA: superficial femoral artery, FV: femoral vein, PA: pseudoaneurysm, A: aneurysm, CIA: common iliac artery, R: right, L: left.

AFM, GE Medical Systems, Milwaukee, WI, USA). In 16 cases, stent-graft deployment was performed via a retrograde femoral approach. In only one case with popliteal pseudoaneurysm, an antegrade femoral approach was preferred. In all cases with iatrogenic femoral AVFs, a flexible 7 Fr, 45-cm-long introducer sheath (Super Arrow-Flex, Arrow International, Reading, PA, USA) was placed across the aortic bifurcation to the contralateral side by the cross-over technique.

Iatrogenic femoral AVFs were a result of arterial puncture during coronary angiography (n=2) or percutaneous transluminal coronary angioplasty and coronary stenting (n=8). These patients were all on anticoagulation and antiplatelet regimens for their coronary artery disease. Symptomatic patients were immediately treated. In asymptomatic patients, ultrasonography guided compression for 20 minutes was attempted three times. Persistent patency of the AVF, despite ultrasonography guided compression, constituted our inclusion criterion in asymptomatic iatrogenic femoral AVF patients. Balloon-expandable stent-grafts, 12-28 mm in length and 4-9 mm expandable in diameter range, one for each lesion, were used. Stent-grafts were crimped manually onto a 5-6 Fr, 5-7 mm peripheral angioplasty balloon (Opta Pro, Cordis Europa, Roden, The Netherlands). The vessel diameter was automatically calculated with reference to the diagnostic catheter, which was used as the baseline for the stent-graft diameter. Roadmap and angiographic control were used for the exact placement of the stent-graft.

Self-expandable stent-grafts, 40-50 mm in length and 6-13 mm expandable in diameter, one for each lesion, were used in cases with axillary (n=1) and popliteal (n=1) pseudoaneurysms, spontaneous iliac aneurysm (n=1) and in one iliac aneurysm associated with obstructive atherosclerotic iliac disease. They were deployed when the appropriate position of the stent-graft was achieved.

All patients were given a 5,000 IU heparin bolus, intra-arterially, during stent-graft placement. Adjunctive therapy after the procedure included low molecular weight heparin (Fraxiparine, Sanofi Pharma, Paris, France) for three days (two doses a day, 0.4 ml per dose, subcutaneously administered), 75 mg clopidogrel per day for one month, and 300 mg acetylsalicylic acid per day for life.

The follow-up protocol included both clinical examination and color Doppler ultrasonography the day after the procedure, and at 1,3, 6, 9, and 12 months, and then annually, unless the patient had any complaints. Intravenous or intraarterial digital subtraction angiography was performed in selected patients who had complaints or positive color Doppler ultrasonography findings. The follow-up period was 1-50 months (mean, 24 months).

Results

In all 17 cases, the stent-grafts were deployed successfully. In iatrogenic femoral fistulas, complete closure of the fistulas was immediately accomplished in 9 of the 10 cases (Figure 1). In one patient with leg edema, complete closure could not be achieved due to short stent-graft selection. Nonetheless, the fact that the complaint subsided was taken to indicate clinical success. Blood flow within the pseudoaneurysms of the axillary artery and the popliteal artery (Figure 2), aneurysm of the iliac artery, and aneurysms associated with atherosclerotic obstructive disease in the iliac arteries (Figure 3) ceased. In the patient with traumatic femoral AVF, the fistula tract between the superficial femoral artery and vein was totally eliminated. However, complete closure of the fistula could not be achieved due to multiple deep femoral artery feeders. As the major feeder of the fistula was eliminated, the leg edema of the patient became asymptomatic and the patient refused further treatment. In the patient with lumbar discectomy-induced iatrogenic AVF between the common iliac artery and vein, only partial closure could be achieved due to short stent-graft selection. Young age and high bifurcation of the internal iliac artery were the reasons for short stent-graft selection in this patient. As the complaints of the patient did not subside, the fistula was surgically eliminated later. This was the only case with insufficient closure of AVF in our patient population.

In patients with subsided complaints, the mean follow-up period was 24 months, which included both clinical examination and color Doppler ultrasonography. Color Doppler ultrasonography revealed patency of the stented segments. Luminal narrowing of not more than 30%, due to intimal hyperplasia, was observed in four of the cath-

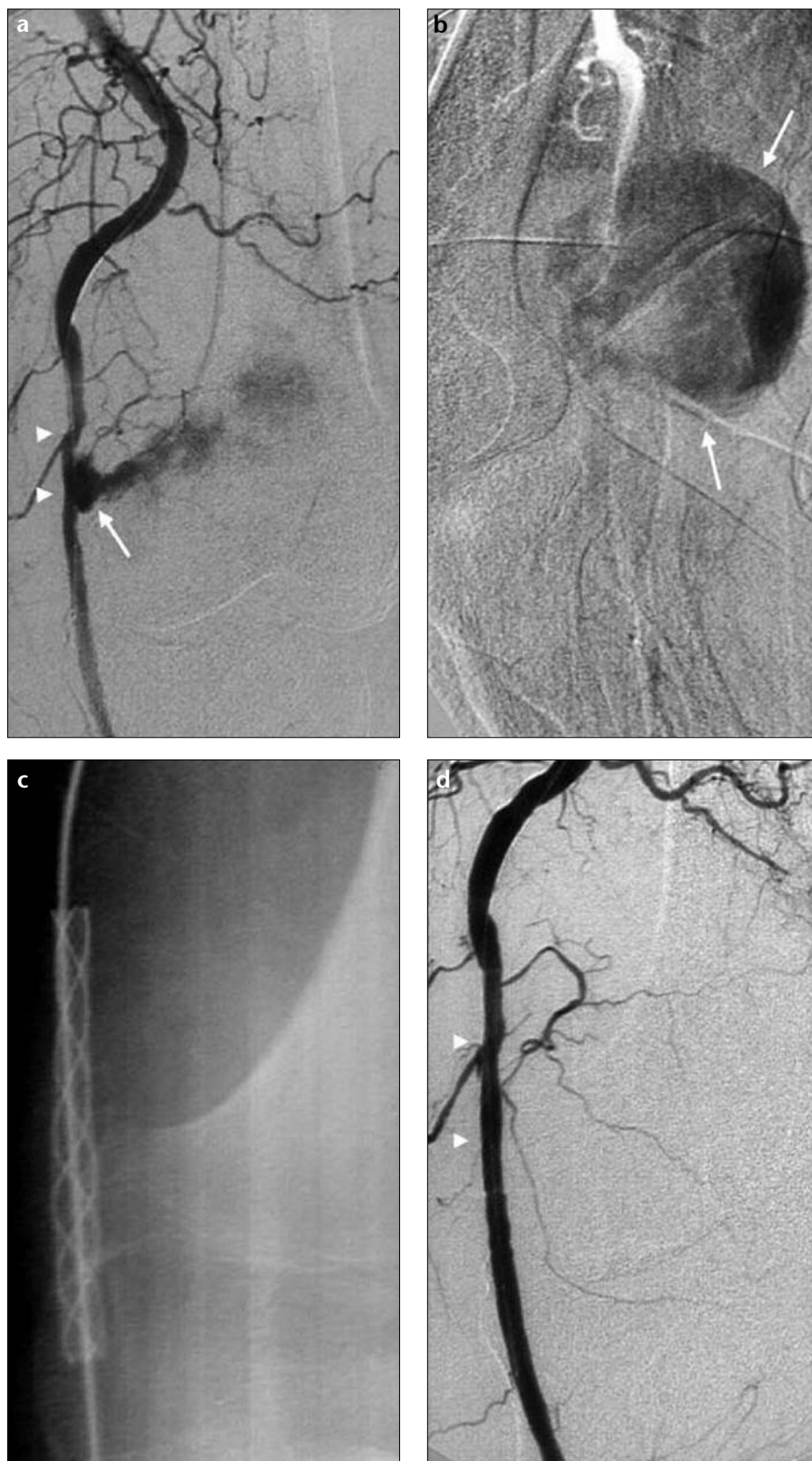


Figure 2. a-d. Selective antegrade injection into the superficial femoral artery shows a pseudoaneurysm of the left popliteal artery in early (a) and late (b) arterial phases (arrows, a and b). Note the arterial irregularity and narrowing due to the compression of the pseudoaneurysm (arrowheads, a). c. Native X-ray shows the implanted stent-graft (Wallgraft, 7 mm in diameter x 40 mm long). d. Angiogram obtained after insertion shows the closure of the pseudoaneurysm. Note the smooth contours of the stented segment (arrowheads).

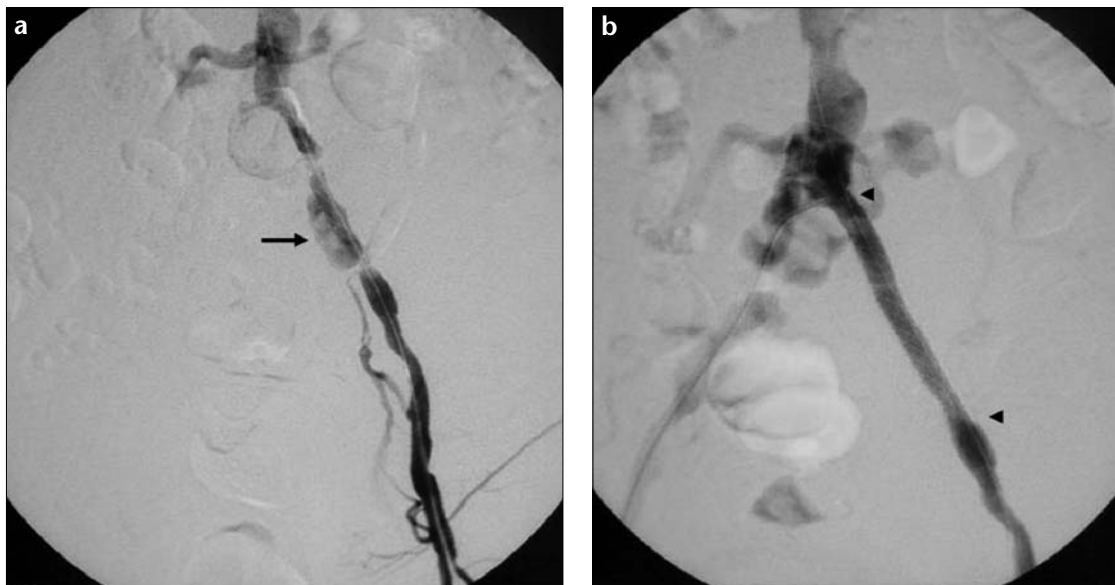


Figure 3. a, b.
a. Non-selective angiogram reveals a left common iliac artery aneurysm (arrow) associated with atherosclerotic plaques. **b.** Angiogram obtained after implantation of a self-expandable stent-graft shows the obliteration of the aneurysm and smooth contours of the stented segment (arrowheads).

eterization-induced AVFs and they had no symptoms in the follow-up period. In the patient with traumatic axillary pseudoaneurysm, prominent intimal hyperplasia was observed at 5 month follow-up, and PTA (percutaneous transluminal angioplasty) was applied to overcome the stenosis. The patient was asymptomatic, with smooth contours of the stented segment at intravenous digital subtraction angiography at 50 month follow-up.

Discussion

The traditional treatment of peripheral arterial aneurysms, pseudoaneurysms, AVFs, arterial ruptures, and perforations is surgical intervention. However, endovascular stent-graft placement is gaining popularity as a therapeutic alternative to open surgery (4-7). This procedure can be done under local anesthesia, is well tolerated by the patient, and is associated with a shorter hospitalization time than that of surgery. Surgical complications such as hemorrhage and infection, as well as the risk of general anesthesia, can be avoided in endovascular treatment. On the other hand, endovascular therapeutic approaches have their own complications such as stent occlusion, stent deformation and kinking, the loss of vessel branches after placement, and intimal hyperplasia (4, 6, 10, 11).

Careful observation and ultrasonography guided compression have been suggested as first line therapies in the management of post catheterization femoral AVFs because of their noninvasive nature (12-14). However, the fact that these patients are all on anti-

coagulation and antiplatelet regimens for their coronary artery disease makes the spontaneous closure, or successful compression-obliteration of an iatrogenic AVF less likely (13-15). Post-catheterization femoral AVFs can originate from the common, superficial, or deep femoral arteries. Possible risk factors that increase the likelihood of post-cardiac catheterization AVF complications include distal puncture, older age, female gender, and periprocedural and post-procedural anticoagulation and antiplatelet therapy. We believe that distal puncture was the main reason for the dominance of AVFs between the deep femoral artery and the superficial femoral vein in our group of patients. Reports related to pseudoaneurysms and AVFs after catheterization also show that these complications are highly associated with puncture sites below the level of the femoral head (13-15). The common femoral artery is in close proximity to the posteriorly located femoral head and the superior pubic ramus. Posterior support is provided by these bony structures during arterial compression in patients who had a common femoral artery puncture. However, the deep or superficial femoral artery lacks this bony support, and therefore hemostasis may be difficult to achieve during arterial compression after catheter removal, if the puncture site is distal to the common femoral artery. In cases of low arterial puncture, it is likely that the needle first enters a branch of the superficial femoral vein, which is located ventral

to the deep femoral artery. Subsequent placement of the arterial sheath leads to creation of the AVF (16-18). We treated catheter-induced fistulas originating from the deep femoral artery. Complete closure of the fistulas was immediately accomplished in 9 of the 10 cases. In one case, complete closure could not be obtained, but due to the fact that the complaint subsided, it was considered a clinical success.

In the treatment of atherosclerotic disease in iliac arteries, some increasingly favor the use of stent-grafts, with reasonable one year primary patency rates of 91%-97% (19-21). This treatment, however, still remains questionable, since only limited data are available on the benefits of using stent-grafts to treat atherosclerotic disease. The follow-up results after PTA or stenting in iliac arteries are so favorable that the use of a stent-graft is unlikely to improve patency rates. This is also true for complex lesions, where bare stents have already proven their efficacy (22). However, metallic stents are usually appropriate for focal, predominantly stenotic arterial lesions and treatment of iliac aneurysms associated with atherosclerotic plaques requires implantation of a stent-graft because of the need to reliably seal the entrance of the intramural channel. We successfully treated three patients with iliac aneurysms associated with atherosclerotic plaques.

The use of subclavian venous catheterization is the main reason for damage to the subclavian artery at the access site and the resulting pseudoaneurysm.

However, our case with subclavian artery pseudoaneurysm was due to penetration trauma. Until recently, the treatment of choice would have been surgical intervention, because of the non-compressible nature of the region and its close proximity to intrathoracic structures. There are now many reports of endovascular treatment of subclavian artery pseudoaneurysms in the literature (4, 23, 24). Endovascular treatment with stent-grafts in the femoropopliteal region has also been reported (11, 25).

Peripheral stent-grafts, either balloon-expandable or self-expandable, have their own advantages and disadvantages. Although balloon-expandable stent-grafts provide accurate sizing and localization, self-expanding stent-grafts are preferred as the first choice due to their flexibility and resistance to external forces in superficial locations like the groin. As we pointed out earlier, balloon-expandable stent-grafts are prone to collapse due to external forces. Substantial flexing may lead to an additional risk of compression or kinking. Using the shortest stent-graft possible is recommended to avoid these complications, as well as to reduce the risk of involuntary closure of the side branches (8, 26). We did not confront any collapse or kinking in the follow-up period in patients with iatrogenic femoral AVFs, although we used balloon-expandable stent-grafts, because the proximal deep femoral artery is far enough away from the hip joint and is sufficiently protected. Side branch occlusion, a potential consequence of implantation of a stent-graft in the deep femoral artery, was encountered in three of our patients, but remained clinically asymptomatic.

Although elective vascular lesions such as pseudoaneurysms and AVFs can be treated either with surgery or an endovascular approach, in emergency cases time is limited. Therefore, iatrogenic vascular injuries, such as perforations due to catheterization and interventional techniques, or traumatic injuries, should be treated by the interventional radiologist. This requires the availability of peripheral stent-grafts in the angiography units for urgent cases.

Stent-grafts could have disadvantages for younger patients with long life expectancy, since the long-term consequences of implanting stent-grafts are not known for certain. Therefore, young

patients who are good candidates may warrant surgery rather than stent implantation, except in emergency cases.

In conclusion, our results suggest that endovascular treatment with stent-grafts is a low-risk procedure, which appears to be less invasive than surgery for the treatment of various types of peripheral vascular lesions.

References

- Dotter CT. Transluminally placed coil spring endarterial tube grafts: long term patency in canine popliteal artery. *Invest Radiol* 1969; 4:329-332.
- Balko A, Piasecki GJ, Shar DM, Carney WI, Hopkins RW, Jackson BT. Transfemoral placement of intraluminal polyurethane prosthesis for abdominal aortic aneurysm. *J Surg Res* 1986; 40:305-309.
- Parodi JC, Palmaz JC, Barone HD. Transfemoral intraluminal graft implantation for abdominal aortic aneurysms. *Ann Vasc Surg* 1991; 5:491-499.
- Baltacıoğlu F, Çimşit NÇ, Çil B, Çekirge S, İspir S. Endovascular stent-graft applications in iatrogenic vascular injuries. *Cardiovasc Intervent Radiol* 2003; 26:434-439.
- Thalhammer C, Kirchherr AS, Uhlich F, Waigand J, Gross CM. Postcatheterization pseudoaneurysms and arteriovenous fistulas: repair with percutaneous implantation of endovascular covered stents. *Radiology* 2000; 214:127-131.
- Nyman U, Uher P, Lindh M, Lindblad B, Brunkwall J, Ivancev K. Stent-graft treatment of iatrogenic iliac artery perforations: report of three cases. *Eur J Vasc Endovasc Surg* 1999; 17:259-263.
- Aytekin C, Boyvat F, Yıldırım E, Coşkun M. Endovascular stent-graft placement as emergency treatment for ruptured iliac pseudoaneurysm. *Cardiovasc Intervent Radiol* 2002; 25:320-322.
- Önal B, Kosar S, Gumus T, Ilgit ET, Akpek S. Postcatheterization femoral arteriovenous fistulas: endovascular treatment with stent-grafts. *Cardiovasc Intervent Radiol* 2004; 27:453-458.
- Oktar GL, Balkan ME, Akpek S, Ilgit E. Endovascular stent-graft placement for the management of a traumatic axillary artery pseudoaneurysm: a case report. *Vasc Endovascular Surg* 2002; 36:323-326.
- Cejna M, Virmani R, Jones R, et al. Biocompatibility and performance of the Wallstent and several covered stents in a sheep iliac artery model. *J Vasc Interv Radiol* 2001; 12:351-358.
- Beregi J-P, Prat A, Willoteaux S, Vasseur M-A, Boularand V, Desmoucelle F. Covered stents in the treatment of peripheral arterial aneurysms: procedural results and midterm follow-up. *Cardiovasc Intervent Radiol* 1999; 22:13-19.
- Kelm M, Perings SM, Jax T, et al. Incidence and clinical outcome of iatrogenic femoral arteriovenous fistulas: implications for risk stratification and treatment. *J Am Coll Cardiol* 2002; 40:291-297.

- Schaub F, Theiss W, Heinz M, Zigel M, Schömig A. New aspects in ultrasound-guided compression repair of postcatheterization femoral artery injuries. *Circulation* 1994; 90:1861-1865.
- Fellmeth BD, Roberts AC, Bookstein JJ, et al. Postangiographic femoral artery injuries: nonsurgical repair with US-guided compression. *Radiology* 1991; 178:671-675.
- Kresowik TF, Khoury MD, Miller BV, et al. A prospective study of the incidence and natural history of femoral vascular complications after percutaneous transluminal coronary angioplasty. *J Vasc Surg* 1991; 13:328-336.
- Altin RS, Flicker S, Naidech HJ. Pseudoaneurysm and arteriovenous fistula after femoral artery catheterization: association with low femoral punctures. *AJR Am J Roentgenol* 1989; 152:629-631.
- Rapoport S, Sniderman KW, Morse SS, et al. Pseudoaneurysm: a complication of faculty technique in femoral arterial puncture. *Radiology* 1985; 154:529-530.
- Grier D, Hartnell G. Percutaneous femoral artery puncture: practice and anatomy. *Br J Radiol* 1990; 63:602-604.
- Henry M, Amor M, Cragg A, et al. Occlusive and aneurysmal peripheral arterial disease: assessment of a stent-graft system. *Radiology* 1996; 201:717-724.
- Lammer J, Dake MD, Bleyn J, et al. Peripheral arterial obstruction: prospective study of treatment with a transluminally placed self-expanding stent-graft. International Trial Study Group. *Radiology* 2000; 217:95-104.
- Rzucidlo EM, Powell RJ, Zwolak RM, et al. Early results of stent-grafting to treat diffuse aortoiliac occlusive disease. *J Vasc Surg* 2003; 37:1175-80.
- Vorwerk D, Günther RW. Percutaneous interventions for treatment of iliac artery stenoses and occlusions. *World J Surg* 2001; 25:319-327.
- Bartorelli AL, Trabattini D, Agrifoglio M, et al. Endovascular repair of iatrogenic subclavian artery perforations using the Hemobahn stent-graft. *J Endovasc Ther* 2001; 8:417-421.
- Pastores SM, Marin ML, Veith FJ, Bakal CW, Kvetan V. Endovascular stented graft repair of a pseudoaneurysm of the subclavian artery caused by percutaneous internal jugular vein cannulation: case report. *Am J Crit Care* 1995; 4:472-475.
- Sharma S, Bhargava B, Mahapatra M, Malhotra R. Pseudoaneurysm of the superficial femoral artery following accidental trauma: results of treatment by percutaneous stent-graft placement. *Eur Radiol* 1999; 9:422-424.
- Ruebben A, Tettoni S, Muratore P, Rossato D, Savio D, Rabbia C. Arteriovenous fistulas induced by femoral arterial catheterization: percutaneous treatment. *Radiology* 1998; 209:729-734.