

The role of classic spin echo and FLAIR sequences for the evaluation of myelination in MR imaging

Betül Kızıldağ, Ebru Düşünceli, Suat Fitoz, İlhan Erden

PURPOSE

The aim of this study was to assess the features of the normal brain development in terms of myelination in infants and young children on fluid-attenuated inversion recovery (FLAIR) magnetic resonance (MR) imaging, and to determine if FLAIR imaging is superior to spin echo MR sequences.

MATERIALS AND METHODS

T1-weighted (T1W) fast spin echo T2-weighted (FSE T2W), and FLAIR images were obtained in 76 pediatric patients between the ages of 0 and 48 months, on a 1 Tesla MR unit. On these images, the signal intensities of 16 different white matter regions were compared to those of adjacent gray matter, and for each brain region. Comparisons between the gray and white matter signal intensities were scored by the consensus of two radiologists on a scale of -1 to +1 for each patient.

RESULTS

In the first 6 months, hypointense white matter signal intensity changed to hyperintensity on T1W images. After the first 6 months, white matter progressed from hyperintense to hypointense on T2W images. Except for the cerebral white matter, FLAIR images showed the same signal transition, though slightly later than what was seen on T2W images. The deep cerebral white matter, which was hypointense on birth, became hyperintense early in the first several months of life, and finally, reconverted to hypointense during the second year of life on FLAIR images.

CONCLUSION

Myelination, which is an indicator of brain maturation, was successfully demonstrated both in classic spin echo sequences and on FLAIR images. These imaging techniques are an essential component of routine MR imaging of the dating of and differentiation between normal and pathological brain development.

Key words: • magnetic resonance imaging • myelination • brain

White matter, which forms the majority of the central and peripheral nervous systems, primarily consists of myelin. Myelination, one of the key steps of nervous system development, is in fact a process that starts in the second trimester of fetal development. As an indicator of maturation, myelination continues until adulthood, although it is most rapid during the first two years after birth. Therefore, magnetic resonance (MR) imaging is used as an objective method for the evaluation of developmental delays of the nervous system within this period. In contrast to computed tomography (CT) and ultrasonography, with which pathologies can not be demonstrated except when there are significant white matter changes, information related to the myelin structure and myelination process can be obtained with MR imaging. This ability of MR imaging has been the focus of numerous studies related to this process. Today, in addition to normal developmental processes, changes in pathological development such as metabolic diseases can be evaluated with MR imaging, which is the only method available that allows for the evaluation of myelination *in vivo* (1-8).

Changes related to myelination on T1- and T2-weighted (T1W, T2W) images have been studied by many authors. Fluid-attenuated inversion recovery (FLAIR) imaging, which has recently become a must in routine pediatric brain MR studies, is a technique that forms image contrast based on T1 and T2 relaxation times. Cerebrospinal fluid (CSF) signals are suppressed using an appropriate inversion time with FLAIR pulse sequence, in order to obtain heavily T2W images. Suppression of CSF signal enhances the detection of lesions adjacent to the ventricles (7, 8). In this regard, the study of signal changes during the myelination process using FLAIR imaging has become extremely important in differentiating pathological processes from normal ones. Diffusion tensor imaging, which has been recently developed, is a technique sensitive to even the smallest movements of water molecules, allowing for quantitative measurement of anisotropic changes observed during maturation (1-5). Currently, not all imagers have been equipped with the appropriate software and hardware for this technique and therefore classic spin echo sequences and FLAIR imaging remain valuable techniques.

In this study, our aim was to demonstrate the properties of the normal brain in newborns and infants with FLAIR images and define its place in comparison to classic sequences.

Materials and methods

A total of 76 cases, including 25 girls and 51 boys, with ages ranging from 0 to 48 months were included in the study. All cases were referred for routine cranial MR examination with suspected or diagnosed central nervous system diseases. The cases were summarized in Table 1 according to patient age. The clinical histories or the causes for MR imaging referral

From the Department of Radiology (E.D. ✉ ebrumd2001@yahoo.com), Ankara University School of Medicine, Ankara, Turkey.

Received 26 November 2004; revision requested 17 January 2005; revision received 13 June 2005; accepted 15 June 2005.

Table 1. Numbers of cases in the study by age intervals

Months of age	Number of patients
0-3	11
4-6	9
7-9	6
10-12	7
13-18	6
19-24	11
25-36	14
37-48	12

were developmental delay, tumor, cerebral palsy, mental/motor retardation, epilepsy, trauma, attention deficit-hyperactivity disorder, metabolic diseases, tuberous sclerosis, trisomy 21, and congenital anomalies (arthrogryposis multiplex, meningocele, Beckwith-Wiedemann syndrome, congenital giant melanocytic nevus, etc.).

MR imaging studies were performed in superconductive MR systems (Signa, GE Medical Systems, Milwaukee, WI, USA). In cases where sedation was needed, i. v. midazolam (Dormicum® 0.1 mg/kg) or oral hydroxyzine hydrochloride (Atarax® 5-15 mg/day)

was used. Routine cranial studies were done using a head coil with T1W, fast spin echo (FSE) T2W, and FLAIR images in transverse plane, T2W images in coronal plane, and T1W images in sagittal plane. T1W, T2W, and FLAIR sequences in transverse plane were included for the evaluation of myelination. Parameters related to these evaluations are listed in Table 2.

All the images were retrospectively analyzed by two radiologists. For each case, signal intensities of 16 different brain segments (i. e., pons tegmentum [dorsal pons], middle cerebellar peduncle, crus cerebri, peridentate white matter, optic radiations, internal capsule posterior limb, corpus callosum splenium, corpus callosum genu, centrum semiovale [adjacent to paracentral sulcus], occipital central, and peripheral white matter, frontal central and peripheral white matter, and temporal central and peripheral white matter), where white matter was predominant, were compared with the gray matter in transverse plane T1W, FSE T2W, and FLAIR images. Similar to the scoring technique stated in the literature (6-8), hypointense areas as compared to the gray matter were graded as -1, isointense areas as 0, and intense areas as +1, by a consensus of both radiologists. The changes in signal evolution were matched with age and compared in T1W, T2W, and FLAIR images. The average values of signal changes, as compared with age, were defined in the specified regions (Table 3). Cases in which delayed myelination was detected in classic spin echo sequences were excluded from the study.

Table 2. MR imaging sequence parameters used in the study

Sequence	Slice thickness (mm)	TR (ms)	TE (ms)	TI (ms)	FOV (cm)	NEX	Matrix	Time (min:sec)
T1W	4-5	460-540	12-14		22x16	2-5	256x192	2:16
FSE T2W	4-5	3700-5160	79-113		22x16	2-4	320x224	2:50
FLAIR	4-5	9002-10002	99-105	2050-2300	22x22	1	256x160	3:00

TR: time to repeat, TE: time to echo, TI: time of inversion, FOV: field of view, NEX: number of excitations

Table 3. Ages in which signal changes on three MR sequences were observed related to myelination

White matter region	T1W sequence	T2W sequence	FLAIR sequence
Pons tegmentum (dorsal pons)	Birth	Birth-1st month	3rd-4th month
Middle cerebellar peduncle	Birth	Birth-1st month	3rd-4th month
Crus cerebri	3rd month	3rd month	4th-5th month
Peridentate white matter	3rd month	3rd month	6th month
Optic radiation	4th month	5th-6th month	6th month
Internal capsule posterior limb	Birth	Birth	3rd month
Internal capsule anterior limb	3rd month	6th month	8th-9th month
Corpus callosum splenium	3rd-4th month	3rd-4th month	6th month
Corpus callosum genu	4th-5th month	5th-6th month	6th-7th month
Centrum semiovale	Birth	1st month	4th-5th month
Occipital central white matter	4th month	7th month	2-3rd to 12th month ^a
Frontal central white matter	6th month	11th month	2-3rd to 14th month ^a
Temporal central white matter	8th month	12th month	2-3rd to 22nd month ^a
Occipital peripheral white matter	6th-7th month	11th month	14th month
Frontal peripheral white matter	11th month	18th month	20th month
Temporal peripheral white matter	12th month	20th-22nd month	24th month

^a Triphasic signal change in the cerebral hemispheric white matter in comparison with the adjacent gray matter; first signal change from hypointensity to hyperintensity, second signal change from hyperintensity to hypointensity.

Results

Image quality in all 76 cases included in the study was technically adequate. The radiological findings were not compatible with a delay of myelination or dis-/demyelinating pathologies.

On T1W images, the evolution of white matter hypointensity in the first six months of life to adult form hyperintensity took twelve months. The average age in which white matter regions turn into hyperintense areas secondary to myelination was calculated (Table 3). Accordingly, hyperintensity was present in the pons dorsal region, middle cerebellar peduncle, internal capsule posterior limb, and centrum semiovale adjacent to paracentral gyrus, where myelination was already present at birth (Figure 1a-c). Evolution to hyperinten-

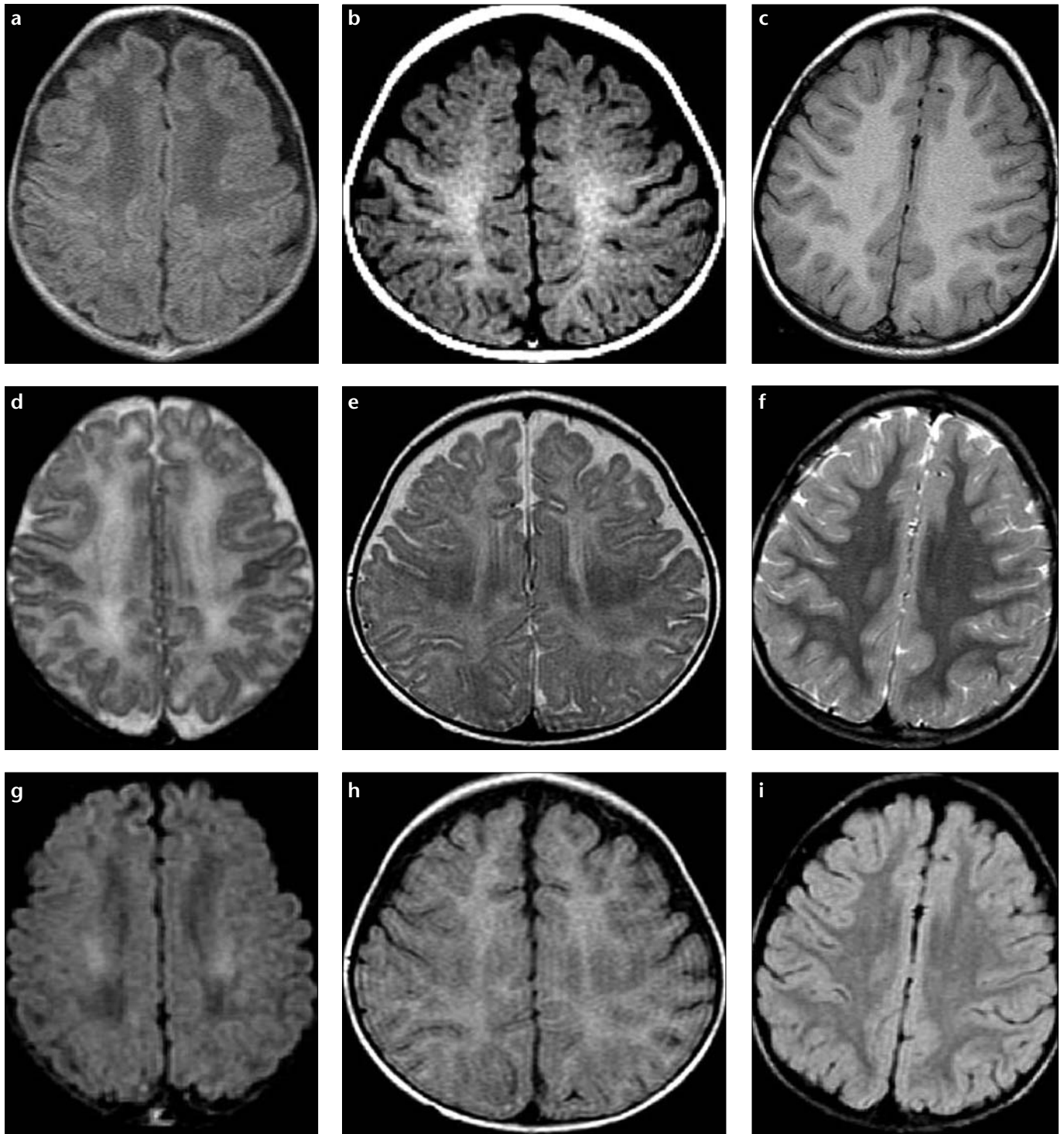


Figure 1. a-i. On transverse T1W (a-c), T2W (d-f), and FLAIR (g-i) MR images of an 8-day-old newborn (a, d, g), 6-month-old infant (b, e, h), and 25-month-old infant (c, f, i), signal changes were observed in the myelinated white matter tracts in the centrum semiovale at the level of the paracentral gyrus. These areas, which were hyperintense from birth on T1W images (a-c), are hyperintense on T2W images in the newborn (d) and hypointense in the sixth month (e) and the twenty-fifth month (f). Signal changes similar to T2W images were observed on FLAIR sequences (i).

sity was visualized in the third month in crus cerebri, peridentate white matter, and internal capsule anterior limb, whereas it was observed in the optic radiation in the fourth month, in the corpus callosum

splenium in the third-fourth months, and in the corpus callosum genu in the fourth-fifth months. Signal changes related to myelination were detected in the central regions of cerebral hemispheric

white matter starting from the occiput in the fourth month, progressing to frontal regions in the sixth month, and temporal regions in the eighth month (Figure 2a-c). Myelination progressed to the cortical

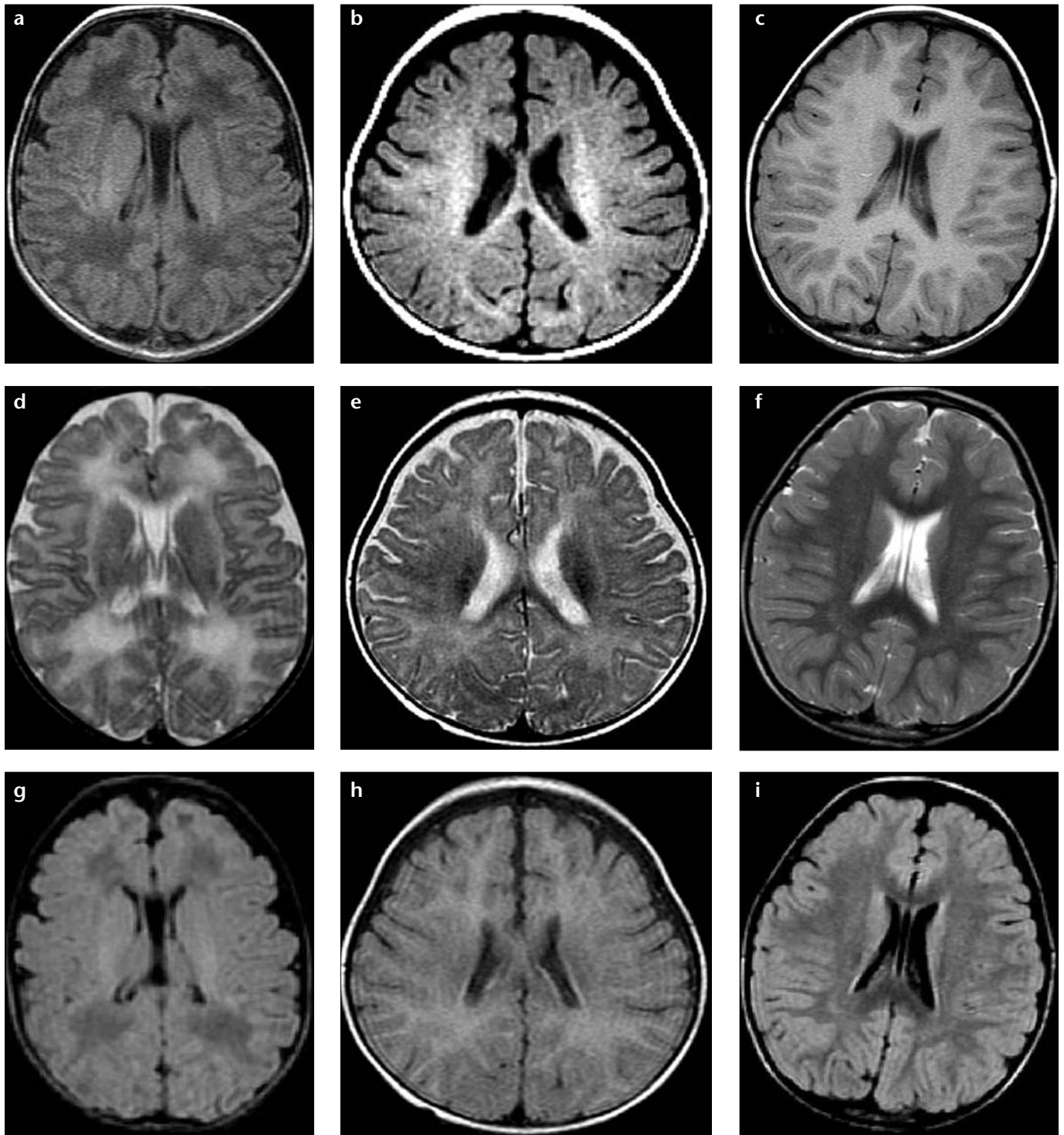


Figure 2. a-i. On transverse T1W (a-c), T2W (d-e), and FLAIR (g-i) images of an 8-day-old newborn (a, d, g), 6-month-old infant (b, e, h), and 25-month-old infant, signal changes in the deep white matter of the occipital and frontal lobes were visualized. The cerebral white matter in the newborn was hypointense on the T1W image (a) and later became hyperintense in the sixth month (b) and the twenty-fifth month (c). These regions were hyperintense on T2W images in the newborn (d) and the 6-month-old infant (e), and hypointense in the 25-month-old infant (f). On FLAIR images, the mentioned white matter areas were hypointense in the newborn period (g), similar to the T1W image, and demonstrated hyperintensity at the sixth month of age (h), and became hypointense again at the twenty-fifth month of age (i).

convolutions and was detected in the occipitals in sixth-seventh months, frontals in eleventh month, and temporals in twelfth month.

On T2W images during the first two years of life, the white matter hyperintensity changed into hypointensity. Hypointensity was present in the internal

capsule posterior limb at birth. While hypointensity was detected in the first month in the pons dorsal region, middle cerebellar peduncle, and centrum semi-

ovale adjacent to the paracentral gyrus, it was detected in the third month in the crus cerebri and peridentate nucleus (Figure 1d-f). Hypointensity was detected in fifth-sixth month in the optic radiations, sixth month in the inner capsule anterior limb, fourth-fifth month in the corpus callosum splenium, fifth-sixth month in genu, seventh month in the central and deep white matter tracts of occipital lobe, as well as the eleventh month in the frontal and twelfth month in the temporal lobes (Figure 2d-f). Peripheral white matter tracts became hypointense and reached the adult form in the eleventh month in the occipitals, eighteenth month in the frontals, and twentieth-twenty-second month in the temporals.

In conventional spin echo sequences, signal changes related to the myelination process were in biphasic pattern in all brain regions (Table 3).

In white matter regions other than the cerebral hemispheric white matter, although signal changes in FLAIR sequences were delayed as compared to T2W images, they were similar to classic T1W and T2W images, displaying a biphasic pattern. In FLAIR images, changes in terms of hyperintensity to hypointensity as compared with the gray matter were as follows: first in the third month in the internal capsule posterior limb, then the middle cerebellar peduncle and pons dorsal regions in the third and fourth month, in the centrum semiovale adjacent to the paracentral sulcus and crus cerebri in the fourth-fifth month, then the peridentate white matter, optic radiation, and corpus callosum splenium in the sixth month, in the genu in the sixth-seventh month, and later in the inner capsule posterior limb in the eighth-ninth month (Figure 1g-i)

Different from the biphasic white matter signal changes on T1W and T2W images, cerebral white matter signal intensity demonstrated a triphasic pattern in FLAIR images. In our cases, we observed the evolution of cerebral hemispheric white matter from hypointensity to hyperintensity in T1W images in the first year of life in comparison to the gray matter. In the same regions in T2W images, a change from hyperintensity to hypointensity was observed in the eighth-twentieth month as compared with the gray matter. However, in FLAIR images, the hemispheric

white matter appeared heterogeneously hypointense in the newborn and signal intensity changed to hyperintensity around second-third month in the occipital, frontal, and temporal central white matter. Hypointensity was again observed in the twelfth month in the occipitals, fourteenth month in the frontals, and twenty-second month in the temporals (Figure 2 g-i). In the cerebral white matter, myelination started first in the occipital lobes and last in the temporal lobes.

Similar to T1W and T2W images, signal changes in the peripheral white matter followed that of the deep white matter. Change from hypointensity to hyperintensity was detected in the fourteenth month in the occipitals and twentieth month in the frontals. The temporal peripheral white matter was the last region to myelinate and hyperintensity lasted till the twenty-fourth month.

When the scores of the two radiologists were compared, the amount of mismatch was calculated as 7% (45 mismatches in a total of 648 scores). The difference of variation in the scoring system was not more than 1 unit. However, the final decision was reached through the agreement of both radiologists.

Discussion

Myelination, which is a dynamic process in the developing brain, is the most important indicator of brain maturation. MR imaging, which has been in routine use lately, is the only method that allows for the evaluation of myelination *in vivo* (9-12). Changes related to myelination on T1W and T2W images have been extensively studied by many authors (13-19). FLAIR imaging, which has recently become as a must in routine pediatric imaging, has its contrast based on T1 and T2 relaxation times. In this manner, evaluation of signal changes in FLAIR images during the myelination process becomes an important tool to differentiate pathological processes from normal ones (7, 8).

Brain myelination occurs in a predictable and symmetrical sequence following general rules. Generally, myelination in the brain is from caudal to rostral, posterior to anterior, and from central to peripheral (8). Myelination starts in the fourth-fifth months of gestation and completes in the twentieth-twenty-ninth months (8-10, 20,

21). According to the histological data on developing brains, the most active myelin synthesis occurs in the first 8 postnatal months, and the most active period of myelin maturation is the eighth-fifteenth postnatal months (20-21).

The water content of white matter is higher in the neonatal period as compared to older infants. Myelin has relatively less water and because the mature brain contains more white matter, a decrease in the water content of white matter is observed along with maturation (8-11, 23, 24).

While unmyelinated white matter on T1W images has low signal intensity, with myelin maturation it becomes hyperintense. On T2W images, unmyelinated white matter appears hyperintense and is followed by a decrease in signal intensity with maturing myelin (8-11).

This study was performed by retrospective analysis by two experienced radiologists of pediatric brain studies reported to have normal myelination in concordance with age, on transverse T1W, T2W, and FLAIR images. Cases that had pathological clinical findings were also included in the study, because presently there is no information as to whether myelination delay in any of these diseases is predictable. In published reports, the normal myelination process is mentioned, even in cases in which there is a superimposition of pathological delay (17, 25).

In our study, signal changes related to myelination on T1W images were similar in age as has been reported in the literature (Table 3). However, the age of appearance of signal changes on T2W images was earlier than in other studies (16). For instance, splenium and genu of the corpus callosum, internal capsule anterior limb, occipital, as well as frontal and temporal white matter regions were hypointense a few months earlier on T2W images as stated in the literature (16). While T2W images were obtained using conventional spin echo techniques in other studies, in our study, FSE T2W techniques were used (1, 6-8, 13, 16). In accordance with this technical change, hypointensity related to myelin maturation was detected earlier on T2W images. Findings in our study were similar to age related signal changes on T2W images observed in a study by Murakami et al. using FSE T2W sequence (7). With multislice FSE

imaging, the detection of myelination relatively increased in relation to magnetization transfer (7). In addition, an increase in T2 effect secondary to use of longer TR and effective TE values have made detection of myelinated areas easier. These technical differences explain why myelination was detected relatively earlier on T2W images in our study (7, 16).

Image contrast on FLAIR studies are mainly related to T2 relaxation differences, because in many FLAIR protocols longer effective TE values are used (this value was 99 ms in our study). Selection of an inversion pulse with a longer TI value (the TI value in our study was ranging from 2050 to 2300 ms) suppresses the signals from tissues with very long T1 relaxation times. The only tissue that has a high enough relaxation time is the CSF. Similar to our study, on FLAIR images at birth, white matter areas such as pons dorsal regions, cerebellar peduncle, internal capsule posterior limb, and paracentral gyri appear hyperintense in comparison to the gray matter. Over the course of time, the white matter loses intensity gradually, and in FLAIR sequence, the brain reaches an adult pattern by the second year of life. While unmyelinated cerebral white matter shows a triphasic pattern on FLAIR images, there is a biphasic pattern on T1W and T2W images. Because of this, brain maturation can be demonstrated definitively on FLAIR images as compared with T1W and T2W images (7, 8).

Myelin maturation is detected earlier on T1W images than on T2W. Barkovich et al. stated that in the first 6-8 months of life, T1W images are more appropriate to demonstrate myelin maturation and T2W images are more informative after 6 months (8-10). However, in this study FLAIR images more definitively showed the myelination process from beginning to end as compared to T1W and T2W images. In the spin echo sequences still in use, myelinated white matter appears hyperintense on T1W images and hypointense on T2W images at birth. In contrast to spin echo sequences, on FLAIR images, signal intensities change from hyperintense to hypointense in response to the maturation of myelinated white matter. Except in deep cerebral white matter, white matter areas on FLAIR images change from hyperintense to hypointense dur-

ing the first 24 months of life. When the presence of T2 relaxation effects on the fundamentals of FLAIR imaging is known, this finding is not surprising. Previous investigators have linked the decrease in white matter signal intensity on T2W images to compression of the myelin spiral around the axon and myelin juxtaposition, or myelin maturation (7, 13, 15, 19). The observed signal change from hyperintensity to hypointensity on FLAIR images in the white matter occurs a little later than similar changes on T2W images (7). This delay may stem from T1 sensitivity of FLAIR imaging. The tendency of the white matter to be hypointense on FLAIR images, secondary to T2 effect, is partially blocked by T1 relaxation effect (7). The net effect of these contradicting forces on image contrast is a relative delay of white matter signal change on FLAIR images as compared to T2W images.

While the deep cerebral white matter demonstrates triphasic signal changes on FLAIR images, there is a biphasic signal change on T1W and T2W images (7). In infants, hemispheric deep cerebral white matter is more hypointense in comparison to the adjacent gray matter. When the T1W images are compared, these white matter areas are relatively more hypointense when compared with the adjacent white matter. However, on T2W images these areas are more hyperintense. Demonstration of deep white matter as distinct areas is difficult on T1W and T2W images because the background white matter is hypointense on T1W images and hyperintense on T2W images. These areas have relatively higher water content (7, 15, 19). It is estimated that free water, by increasing the T1 value, suppresses the signals, and therefore becomes hypointense like CSF on FLAIR sequences (7, 19).

The second stage of the triphasic FLAIR study occurs within the first few months of life. In our study, at birth hypointensity was observed in the occipital, frontal, and temporal white matter in comparison the adjacent gray matter, and this was similar to T1W images. Later, a change from hypointensity to hyperintensity was visualized in the white matter, starting from the occipital lobe and progressing to the frontal and temporal white matter around the second-third months. In this period, secondary to a decrease

in free water due to myelin formation, there is a decrease in T1 relaxation times. This is thought to contribute to the signal increase in white matter on T1W images (7, 13, 15, 19). At the same time, a decrease in T1 relaxation time prevents the suppression of the deep cerebral white matter along with the inversion pulse related suppression of the CSF pulse. As the T1 relaxation time decreases, the T2 relaxation time becomes dominant in the image contrast. This situation results in relative hyperintensity of the deep cerebral white matter compared to adjacent gray matter on FLAIR images (7).

The third phase of triphasic FLAIR images is observed in the second year of life. In the last phase of this signal change, white matter becomes isointense with gray matter and then becomes hypointense (7). This sequence was analogous to signal changes on T2W images despite a short delay. Changes in the periphery of cerebral white matter followed the changes in the central regions.

In our study, triphasic signal change on FLAIR images was not observed in the other white matter areas, such as the dorsal pons, middle cerebral peduncle, crus cerebri, peridentate white matter, internal capsule anterior and posterior limbs, corpus callosum splenium and genu, and optic radiation. This most likely stemmed from the absence of enough free water in the regions like the middle cerebellar peduncle, peridentate white matter, crus cerebri, corpus callosum splenium and genu, and optic radiation. The small amount of hypointensity in these areas with partial volume effect caused difficulties in decision-making and a lack of correlation between the scores of the two observing radiologists.

Because the temporal lobes are the last regions where myelination is completed after the frontal lobes, the white matter in these lobes remains hyperintense until the twenty-fourth month on FLAIR images (7, 25, 26). In infants within this age group, the normal increase in signal intensity on FLAIR images in the temporal white matter should not be regarded as pathological.

In conclusion, myelination, which is an indicator of brain maturation, was successfully demonstrated both in classic spin echo sequences and on FLAIR images. These imaging techniques are

an essential component of routine MR imaging in the dating of and differentiation between normal and pathological brain development.

References

1. Barkovich AJ. MR of the normal neonatal brain: assessment of deep structures. *AJNR Am J Neuroradiol* 1998; 19:1397-1403.
2. Mukherjee P, Miller JH, Shimony JS, Philip JV, et al. Diffusion-tensor MR imaging of gray and white matter development during normal human brain maturation. *AJNR Am J Neuroradiol* 2002; 23:1445-1456.
3. Miller JH, McKinsty RC, Philip JV, Mukherjee P, Neil JJ. Diffusion-tensor imaging of normal brain maturation: a guide to structural development and myelination. *AJR Am J Roentgenol* 2003; 180:851-859.
4. Engelbrecht V, Scherer A, Rassek M, Witsack HJ, Mödler U. Diffusion-weighted MR imaging in the brain in children: findings in the normal brain and in the brain with white matter diseases. *Radiology* 2002; 222:410-418.
5. McGraw P, Liang L, Provenzale JM. Evaluation of normal age-related changes in anisotropy during infancy and childhood as shown by diffusion tensor imaging. *AJR Am J Roentgenol* 2002; 179:1515-1522.
6. Dietrich RB, Bradley WG, Zaragoza EJ, et al. MR evaluation of early myelination patterns in normal and developmentally delayed infants. *AJR Am J Roentgenol* 1988; 150:889-896.
7. Murakami JW, Weinberger E, Shaw DW. Normal myelination of the pediatric brain imaged with fluid-attenuated inversion-recovery (FLAIR) MR imaging. *AJNR Am J Neuroradiol* 1999; 20:1406-1411.
8. Ashikaga R, Araki Y, Ono Y, Nishimura Y, Ishida O. Appearance of normal brain maturation on fluid-attenuated inversion-recovery (FLAIR) MR images. *AJNR Am J Neuroradiol* 1999; 20:427-431.
9. Barkovich AJ. *Pediatric Neuroimaging*. 2nd ed. New York: Raven Press, 1995; 9-55, 177-277.
10. Barkovich AJ, Kjos BO, Jackson DE Jr, Dorman D. Normal maturation of the neonatal and infant brain: MR imaging at 1.5 T. *Radiology* 1988; 166:173-180.
11. Bird CR, Hedberg M, Drayer BP, Keller PJ, Flom RA, Hodak JA. MR assessment of myelination in infants and children: usefulness of marker sites. *AJNR Am J Neuroradiol* 1989; 10:731-740.
12. Paus T, Collins DL, Evans AC, Leonard G, Pike B, Zijdenbos A. Maturation of white matter in the human brain: a review of magnetic resonance studies. *Brain Res Bull* 2001; 54:255-266.
13. McArdle CB, Richardson CJ, Nicholas DA, et al. Developmental features of the neonatal brain: MR imaging. Part I: gray-white matter differentiation and myelination. *Radiology* 1987; 162:223-229.
14. Staudt M, Schropp C, Staudt F, et al. MRI assessment of myelination: an age standardization. *Pediatr Radiol* 1994; 24:122-127.
15. Girard N, Raybaud C, Du Lac P. MRI study of brain myelination. *J Neuroradiol* 1991; 18:291-307.
16. Grodd W. Normal and abnormal patterns of myelin development of the fetal and infantile human brain using magnetic resonance imaging. *Curr Opin Neurol Neurosurg* 1993; 6:393-387.
17. Daldrup HE, Schuierer G, Link TM, et al. Evaluation of myelination and myelination disorders with turbo inversion recovery magnetic resonance imaging. *Eur Radiol* 1997; 7:1478-1484.
18. Shaw DW, Weinberger E, Astley SJ, Tsuruda JS. Quantitative comparison of conventional spin echo and fast spin echo during brain myelination. *J Comput Assist Tomogr* 1997; 21:867-871.
19. Barkovich AJ, Lyon G, Evrard P. Formation, maturation, and disorders of white matter. *AJNR Am J Neuroradiol* 1992; 13:447-461.
20. Van der Knaap MS, Valk J. *Magnetic Resonance of Myelin, Myelination and Myelin Disorders*. 2nd ed. Berlin: Springer-Verlag, 1995; 1-52.
21. Dobbing J, Sands J. Quantitative growth and development of human brain. *Arch Dis Child* 1973; 48:757-767.
22. Dobbing J. The later development of brain and its vulnerability. In: Davis JA, Dobbing J, eds. *Scientific Foundations of Pediatrics*. London: William Heinemann Medical Books, 1982; 744.
23. Kamman RL, Go KG, Muskiet FAJ, et al. Proton spin relaxation studies of fatty tissue and cerebral white matter. *Magn Reson Imaging* 1984; 2:211-220.
24. Bradley WG, Chen D, Georgen SK, Tam JK, Dubin MD, Pema J. Use of thin section fast FLAIR to evaluate multiple sclerosis. *Radiology* 1994; 183:320.
25. Kinney HC, Brody BA, Kloman AS, Gilles FH. Sequence of central nervous system myelination in human infancy: II. Patterns of myelination in autopsied infants. *J Neuropathol Exp Neurol* 1988; 47:217-234.
26. Brody BA, Kinney HC, Kloman AS, Gilles FH. Sequence of central nervous system myelination in human infancy: I. An autopsy study of myelination. *J Neuropathol Exp Neurol* 1987; 46:283-301.