

A novel index to estimate the corpus callosum morphometry in adults: callosal/supratentorial-supracallosal area ratio

Nuri Erdoğan, Harun Ülger, İbrahim Tuna, Aylin Okur

PURPOSE

To prospectively investigate the feasibility of a new index (callosal/supratentorial-supracallosal area ratio) in morphometric analysis of the corpus callosum in adults.

MATERIALS AND METHODS

The callosal and supratentorial-supracallosal areas of 50 healthy volunteers were measured on T1 weighted midsagittal magnetic resonance images. Mean value and variation coefficient for the index was calculated. In a limited subset of subjects (n=25), an interobserver agreement study was conducted to estimate the reproducibility of the index.

RESULTS

There was a statistically significant difference between the area for corpus callosum and supratentorial-supracallosal regions in males and females, although the calculated ratio (index) had no sex-difference. When compared to the literature, the variation coefficient was relatively lower (12.0%), with good interobserver agreement (Pearson correlation analysis, $r=0.83$).

CONCLUSION

Callosal/supratentorial-supracallosal area ratio might serve as a reliable index in morphometric analysis of the corpus callosum in adults.

Key words: • corpus callosum • magnetic resonance imaging

The corpus callosum (CC) is the most important commissural structure that provides communication between cortical and subcortical neurons of the two cerebral hemispheres (1). Histologically, it consists of myelinated nerve fibers. Morphology of the CC is affected in cases of injury of the communicating neurons or cerebral white matter. It is designated as agenesis or hypogenesis if it is affected before the development is complete and atrophy if it occurs after the completion of development, respectively (2, 3). Magnetic resonance (MR) images in the sagittal plane can be used in detecting the developmental stages and acquired changes of the CC.

In this study, areas of the CC and supratentorial-supracallosal (ST-SC) regions were measured on the midsagittal MR images of healthy volunteers, and a novel morphometric index (CC/ST-SC) was assessed with the ratio of these two measurements. For detecting reproducibility of this index, variation coefficient in the study group and interobserver agreement were calculated. Similar studies are present in literature, but the denominator of the suggested indexes is different (4, 5). A novel index with a better correlation between observers and a lower variation coefficient, in comparison to those in the literature, can provide a more efficient tendency for expression of changes in the midsagittal CC area quantitatively.

Materials and methods

MR images of 50 healthy volunteers (23 male, 27 female) were evaluated prospectively in this study. Mean age of the volunteers was 33.4 years (range, 18-50 years). Examinations were performed on a 1.5T MR Gyroscan NT (Philips Medical Systems, Best, the Netherlands) and T1 weighted sagittal and FLAIR sequences were obtained. The purpose of FLAIR sequences was to exclude those subjects that might have had focal incidental hyperintensities in white matter. People over 50 years of age were not included in the study to exclude the possibility of senile atrophy. T1 weighted MR images were then transferred to another workstation for area measurement. Parameters for T1 weighted images were as follows: FOV: 230 mm, matrix: 256x256, slice thickness: 5 mm, interslice gap: 1 mm, NEX: 2-3, TR/TE: 562/14 msec. Parameters for FLAIR sequence were: FOV: 300 mm, matrix: 256x256, slice thickness: 5 mm, interslice gap: 1 mm, NEX: 2, TR/TE: 4700/100 msec.

One of the midsagittal T1 weighted images which best demonstrated the CC was then selected for evaluation. First, the area inside of a closed line crossing the CC was calculated. Later, ST-SC areas were calculated and proportioned (Figure). While ST-SC ratio was calculated, lines that passed from the inner lamina of dura and calvarium were paid particular attention. The aim of this approach was to not affect the results with cortical gray matter changes. Area measurements were calculated auto-

From the Departments of Radiology (N.E. ✉ nerdogan@erciyes.edu.tr, I.T., A.O.), and Anatomy (H.Ü.) Erciyes University School of Medicine, Kayseri, Turkey.

Received 2 March 2005; revision requested 29 May 2005; revision received 13 July 2005; accepted 17 July 2005.

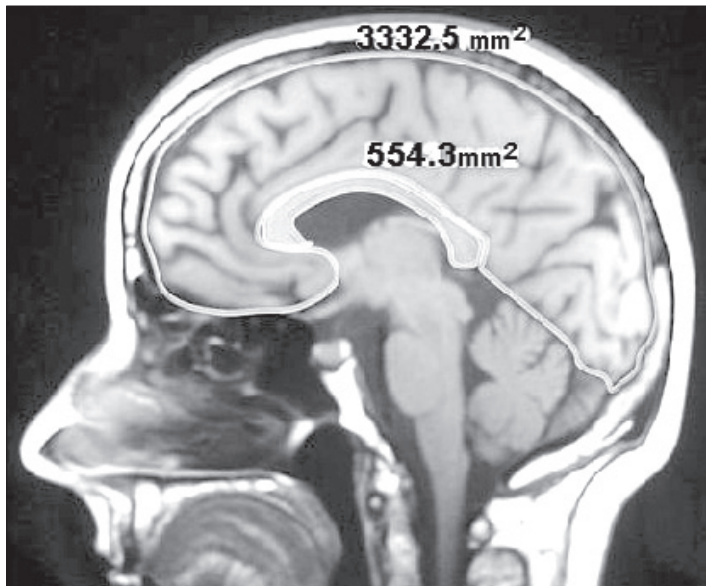


Figure. Sagittal T1-weighted MR image demonstrates the area measurements for index calculation.

matically by the device and had a sensitivity of 0.01 mm².

Index consisting of the areas of CC and ST-SC regions and the ratio of these areas (CC/ST-SC) were calculated separately for males and females and the effect of gender on the results was investigated statistically (Student's t test). In a limited subset of subjects (n=25), an interobserver agreement study was conducted to estimate the reproducibility of the index.

Results

Areas of CC and ST-SC regions were 656.7±83.5 mm² and 8734.4±708.7 mm² for males and 608.4±84.2 mm² and 8149±654.5 mm² for females, respectively (Table). There was a statistically significant difference between the area of CC and ST-SC regions in males and females (p<0.05). Both CC and ST-SC areas were larger in males. The index consisting of the ratio of two areas was close between males and fe-

males (0.075±0.009 and 0.074±0.009, respectively) and there was no gender difference (p>0.05). Variation coefficient (standard deviation×100/mean value) was 12% for the group (n=50). In a limited subset of subjects (n=25), mean index value for the first observer was 0.078±0.0078 and 0.076±0.0070 for the second observer. The difference between results was not statistically significant (p>0.05). Correlation coefficient depicting interobserver agreement was +0.83 (Pearson correlation analysis).

Discussion

There are many factors affecting the morphology of the CC. The most important ones are developmental anomalies, myelination disorders, and degenerative, ischemic, or traumatic loss of axons (6-8). Other factors are gender (9, 10), age (10), demographic differences such as being right- or left-handed (11), schizophrenia (12), and

alcoholism (13). Changes in configuration of the CC may be diffuse or focal. Subjective evaluation of these changes is expressed in routine MR reports. Numerical expression of changes, especially focal, is different. Anatomic segmentation studies are supposed to detect focal changes, but use of such measurements is not practical (14). In this study, the reproducibility of a novel index, which is dependent upon measurement of the entire CC, was investigated instead of focal changes. Similar studies of these measurements are present in the literature (4, 5). Rauch and Jinkins proportioned the CC area to the mean of the axial and sagittal cerebral areas (5), Laissy et al. proportioned the CC area to the mid-line internal sagittal surface, including the posterior fossa and brain stem (4). Description of the index measured by Laissy et al. is more similar with the index we suggest than is Rauch and Jinkins' (4, 5). The only difference is that in our study ST-SC region's area has been used for calculation of the ratio. This was done because the dura mater makes a good reference line for discrimination of the supratentorial area. Variation coefficient of the ratio calculation (12%) in our study was relatively lower than the value calculated for healthy adults in the study by Laissy et al. (17.4%) (4). In addition to this, high interobserver agreement suggests that the reproducibility of the calculation is high (+0.83). Some points should be emphasized about the index, however. The purpose of the CC/ST-SC area ratio is not to compare the CC to the size of other neuronal structures. Our purpose was to increase the reproducibility of the ratio by using a low variable intracalvarial-calvarial structure. For this reason, particular attention was paid that lines demonstrating ST-SC area cross the dura mater or inner lamina of calvarium. The study group we used for calculation of the index consisted of adults. In pediatric groups, incompleteness of the CC development or relatively high incidence of anomalies like craniosynostosis and microcephaly makes the measurements of CC and ST-SC areas variable. For this reason, a pediatric equivalent of the suggested index should be investigated in future studies.

In conclusion, the index we are suggesting might serve as a reliable tool in morphometric analysis of the CC for

Table. Statistical data of the index values of the callosal and supratentorial-supracallosal areas, and the ratio of the areas in adults

	Females (n=27)	Males (n=23)	Total (n=50)	t-test
Callosal area (mm ²)	608.4±84.2	656.7± 83.5	631.5±86.7	p<0.5
Supratentorial-supracallosal area (mm ²)	8149.0±654.5	8734.4±708.7	8429.0±737.3	p<0.5
Ratio	0.074±0.009	0.075±0.009	0.074±0.009	p>0.5
Variation coefficient	0.12	0.12	0.12	

evaluation of conditions such as developmental deficiency (hypogenesis) or atrophy secondary to diffuse white matter loss, although it is not sensitive to focal changes of the CC.

References

1. Fundamentals of the nervous system. In: deGroot J, Chusid JG, eds. Correlative Neuroanatomy. 21st ed. Sydney: Prentice-Hall, 1991; 1-5.
2. Barkovich AJ. Analysing the corpus callosum. *AJNR Am J Neuroradiol* 1996; 17:1643-1645.
3. Barkovich AJ, Norman D. Anomalies of the corpus callosum: correlation with further anomalies of the brain. *AJNR Am J Neuroradiol* 1988; 151:171-179.
4. Laissy JP, Patrux B, Duchateau C, Hannequin D, Hugonet P, Ait-Yahia H, Thiebot J. Midsagittal MR measurements of the corpus callosum in healthy subjects and diseased patients: a prospective study. *AJNR Am J Neuroradiol* 1993; 14:145-154.
5. Rauch RA, Jinkins JR. Analysis of cross-sectional area measurements of the corpus callosum adjusted for brain size in male and female subjects from childhood to adulthood. *Behav Brain Res* 1994; 64:65-78.
6. Hampel H, Teipel SJ, Alexander GE, et al. Corpus callosum atrophy is a possible indicator of region- and cell type-specific neuronal degeneration in Alzheimer disease. *Arch Neurol* 1998; 55:193-198.
7. Uchino A, Kato A, Yuzuriha T, Takashima Y, Kudo S. Cranial MR imaging of sequelae of prefrontal lobotomy. *AJNR Am J Neuroradiol* 2001; 22:301-304.
8. Meguro K, Constans JM, Courtheoux P, Theron J, Viader F, Yamadori A. Atrophy of the corpus callosum correlates with white matter lesions in patients with cerebral ischaemia. *Neuroradiology* 2000; 42:413-419.
9. De Lacoste-Utamsing MC, Holloway RL. Sexual dimorphism in the human corpus callosum. *Science* 1982; 216:1431-1432.
10. Salat D, Ward A, Kaye JA, Janowsky JS. Sex differences in the corpus callosum with aging. *Neurobiol Aging* 1997; 18:191-197.
11. Witelson SF. The brain connection: the corpus callosum is larger in left-handers. *Science* 1985; 229:665-668.
12. Woodruff PW, McManus IC, David AS. Meta-analysis of corpus callosum size in schizophrenia. *J Neurol Neurosurg Psychiatry* 1995; 58:457-461.
13. Hommer D, Moneman R, Rawlings R, Ragan P, Williams W, Rio D, Eckardt M. Decreased corpus callosum size among alcoholic women. *Arch Neurol* 1996; 53:359-363.
14. Toga AW, Thompson PM. Maps of the brain. *Anat Rec* 2001; 265:37-53.