

Multiparametric MRI guidance in first-time prostate biopsies: what is the real benefit?

Ömer Acar
Tarkan Esen
Bülent Çolakoğlu
Metin Vural
Aslıhan Onay
Yeşim Sağlıcan
Barış Türkbey
İzzet Rozanes

PURPOSE

With the increased recognition of the capabilities of prostate multiparametric (mp) magnetic resonance imaging (MRI), attempts are being made to incorporate MRI into routine prostate biopsies. In this study, we aimed to analyze the diagnostic yield via cognitive fusion, transrectal ultrasound (TRUS)-guided, and in-bore MRI-guided biopsies in biopsy-naïve patients with positive findings for prostate cancer screening.

METHODS

Charts of 140 patients, who underwent transrectal prostate biopsy after the adaptation of mp-MRI into our routine clinical practice, were reviewed retrospectively. Patients with previous negative biopsies (n=24) and digital rectal examination findings suspicious for \geq cT3 prostate cancer (n=16) were excluded. T2-weighted imaging, diffusion-weighted imaging, and dynamic contrast-enhanced imaging were included in mp-MRI. Cognitive fusion biopsies were performed after a review of mp-MRI data, whereas TRUS-guided biopsies were performed blinded to MRI information. In-bore biopsies were conducted by means of real-time targeting under MRI guidance.

RESULTS

Between January 2012 and February 2014, a total of 100 patients fulfilling the inclusion criteria underwent TRUS-guided (n=37), cognitive fusion (n=49), and in-bore (n=14) biopsies. Mean age, serum prostate specific antigen level, and prostate size did not differ significantly among the study groups. In TRUS-guided biopsy group, 51.3% were diagnosed with prostate cancer, while the same ratio was 55.1% and 71.4% in cognitive fusion and in-bore biopsy groups, respectively ($P = 0.429$). Clinically significant prostate cancer detection rate was 69.1%, 70.3%, and 90% in TRUS-guided, cognitive fusion, and in-bore biopsy groups, respectively ($P = 0.31$). According to histopathologic variables in the prostatectomy specimen, significant prostate cancer was detected in 85.7%, 93.3%, and 100% of patients in TRUS-guided, cognitive fusion, and in-bore biopsy groups, respectively.

CONCLUSION

In the first set of transrectal prostate biopsies, mp-MRI guidance did not increase the diagnostic yield significantly.

Transrectal ultrasound-guided prostate biopsy (TRUS-guided) to diagnose prostate cancer is currently estimated to be performed in one million men annually in the USA (1). The original random systematic, six-core transrectal prostate biopsy, initially described by Stamey in 1989 (2), has incorporated more cores over time, with laterally directed 12–14 cores being an accepted practice standard. The major limitation of random systematic sampling is that; clinically insignificant cancers are often identified by chance and affect survival data due to lead and length time bias from overdiagnosis and overtreatment of indolent disease (3). Unlike the diagnostic pathways for other organ cancers, which include direct visual or radiologic guidance, the prostate is being sampled by way of standardized, systematic but essentially random approaches.

With the aid of multiparametric MRI of the prostate (mp-MRI), clinically relevant localized prostate cancer foci may be identified, selectively sampled, and treated (4–6). Hence attempts are being made to incorporate mp-MRI into routine prostate biopsies. Techniques of MRI-targeted biopsy include visual estimation TRUS-guided biopsy (cognitive fusion); software co-registered MRI-ultrasound TRUS-guided biopsy; and in-bore MRI-guided biopsy.

MRI-guided prostate biopsies are particularly useful in the setting of ongoing clinical suspicion of prostate cancer despite previous negative biopsies. Among men with a pre-

From the Departments of Urology (O.A. ✉ omer_acar@hotmail.com, T.E.), and Radiology (A.O., I.R.), Koç University School of Medicine, Istanbul, Turkey; the Department of Radiology (B.Ç., M.V.), VKF American Hospital, Istanbul, Turkey; the Department of Pathology (Y.S.), Acıbadem University, School of Medicine, Istanbul, Turkey; Molecular Imaging Program (B.T.), National Cancer Institute, National Institute of Health, Bethesda, Maryland, USA.

Received 11 November 2014; revision requested 17 December 2014; revision received 30 December 2014; accepted 20 January 2015.

Published online 29 May 2015.
DOI 10.5152/dir.2015.46014

vious negative biopsy, 72% to 87% of cancers detected by MRI-guidance are clinically significant (7). Likewise, mp-MRI findings can also be utilized to cognitively tailor the initial transrectal prostate biopsy protocol. Among men with no previous biopsy, MRI increases the frequency of significant cancer detection to 50% in low risk and 71% in high risk patients (7).

In this study, we aimed to compare the diagnostic efficiency of cognitive fusion, TRUS-guided and in-bore biopsies, which were conducted as the initial sampling modality, in terms of detecting clinically significant prostate cancer.

Methods

Study design and patient population

This retrospective study included a total of 140 patients who underwent transrectal prostate biopsy between January 2012 and February 2014, after the adaptation of mp-MRI into our routine clinical practice. Written informed consent was obtained from all patients. Study population was divided into three main groups according to the transrectal biopsy technique (cognitive fusion, TRUS-guided, and in-bore biopsy). In order to construct comparable groups, we excluded patients with previous negative biopsies (n=24) and digital rectal examination (DRE) findings suspicious for \geq cT3 prostate cancer (n=16). Clinical suspicion of prostate cancer, based on elevated prostate specific antigen (PSA) level, DRE findings, positive

family history, abnormal recordings in PSA adjuncts (age-adjusted PSA, PSA velocity, prostate cancer antigen 3 [PCA3] score, prostate health index [PHI]) and suspicious lesions on mp-MRI, were the main indications to proceed with prostate biopsy.

In our routine clinical practice, we make use of mp-MRI in patients who have abnormal PSA values regardless of the results of novel prostate cancer biomarkers (PCA3, PHI, etc.) and the history of prior negative prostate biopsy(ies). In cases with abnormal DRE findings and/or serum PSA elevations which cannot be explained by non-cancerous etiologies (e.g., benign prostatic hyperplasia, prostatitis), considering the age and prostate volume of the patient, mp-MRI was not performed and prostate biopsies were performed with random systematic sampling under TRUS guidance. Additionally, some patients could not be evaluated by mp-MRI because of reimbursement issues.

The patients in the TRUS-guided biopsy group did not undergo pre-biopsy mp-MRI. A total of 14 different regions of the prostate were sampled during TRUS-guided biopsies. In TRUS-guided biopsies, one core was taken from each region.

Cognitive fusion-guided biopsies were performed after the radiologist, who reviewed mp-MRI images, instructed the biopsy operator radiologist about the mp-MRI findings. Being biopsy-naive and having relatively larger (\geq 1 cm) and multifocal lesions on mp-MRI were the indications for cognitive fusion biopsies where the systematic biopsy template was used but this time the radiologist took an additional of 3.2 samples on average (range, 1.4–8) from the regions that were found to harbor suspicious lesions on mp-MRI.

In-bore biopsies were conducted by means of real-time targeting under MRI guidance. In this technique, only the cancer suspicious lesions were targeted and sampled by the radiologist. Indications for in-bore MRI-guided biopsy were prior prostate biopsy(ies) that yielded negative results and the presence of relatively smaller (<1 cm) and fewer (\leq 3) lesions scored as 4 or 5 in prostate imaging-reporting and data system (PI-RADS) and located anteriorly or distal apically.

MRI acquisition

All mp-MRI examinations were performed with a 3.0 Tesla scanner (Magnetom Skyra, Siemens AG), using sixteen channel body

coil. Before MRI, all patients were injected intramuscularly 20 mg of butylscopolamine (Buscopan; Boehringer) to suppress bowel peristalsis. Examinations included two-dimensional T2-weighted imaging, diffusion-weighted imaging (DWI) and dynamic contrast-enhanced (DCE) imaging. Two-dimensional T2-weighted images were obtained in three orthogonal planes (axial, coronal, and sagittal) using T2-weighted turbo spin-echo sequences. DWI was obtained in axial orientation using a spin echo-echo planar imaging sequence with six b-values (0, 50, 250, 500, 800, and 1000 s/mm²) and computed DWI was obtained with computed b values of 1200 and 1500 s/mm². Restriction of diffusion was quantified by the apparent diffusion coefficient (ADC) value. DCE images were obtained using fast three-dimensional T1-weighted gradient echo sequence in axial orientation. Each volumetric acquisition of the DCE sequence had an acquisition time of seven seconds. A total of 35 contrast-enhanced acquisitions were performed. As a contrast agent, bolus injection of gadobenate dimeglumine (Multihance, Bracco SpA) 0.1 mmol/kg was performed with a motorized power injector and followed by a 20 mL flush of saline. The contrast bolus and the saline flush were both administered at a rate of 5 mL/s. Perfusion curves were generated using the image processing features of an MRI computer-aided detection system (DynaCAD Prostate, Invivo Corporation).

Image interpretation

All MR images were independently interpreted in a routine clinical setting by a single radiologist who was informed about the clinical findings of the patients as part of the clinical workflow. Low signal on T2-weighted imaging, low apparent diffusion coefficient (ADC) values (<1000), high signal intensity on high b-value imaging (\geq 800), and type 2-3 enhancement curve after contrast administration were accepted as the main radiologic criteria for mp-MRI positivity for possible prostate malignancy. A score was designated for T2-weighted, DWI, and DCE-MRI within each region of interest according to a five-point scale based on the PI-RADS system (4) as follows: score 1, "clinically significant disease is highly unlikely"; score 2, "clinically significant disease is unlikely to be present"; score 3, "the presence of clinically significant cancer is equivocal"; score 4, "clinically significant cancer is likely to be present"; score 5, "clin-

Main points

- Techniques of MRI-targeted biopsy include visual estimation TRUS-guided biopsy (cognitive fusion); software co-registered MRI-ultrasound TRUS-guided biopsy; and in-bore MRI-guided biopsy.
- We compared the diagnostic yield of cognitive fusion, TRUS-guided and in-bore MRI-guided biopsies in biopsy-naive patients who had suspicious clinical findings regarding prostate cancer.
- As the overall PI-RADS score increased, the probability of diagnosing prostate cancer and discovering a clinically significant cancer got higher.
- Although overall prostate cancer detection rate and the probability of discovering a clinically significant prostate cancer were higher in the MRI-guided biopsy groups than the TRUS-guided biopsy group, the differences were not statistically significant.

ically significant cancer is highly likely to be present." An overall score representing the impression of the radiologist was given for the whole prostate based on the scores of the index lesion.

Cognitive fusion-guided biopsy technique

TRUS-biopsy technique was generally the same in TRUS-guided and cognitive fusion biopsy groups. Cognitive fusion biopsies were performed in a separate session after an average of 26.5 days (range, 3–389 days) following the initial tumor localization by mp-MRI. The biopsy operator (radiologist), who has been performing TRUS-guided biopsies for 10 years, had direct access to the MRI data and he was informed about the location of cancer suspicious lesions by the other radiologist who reviewed the mp-MRI data. A laterally directed systematic TRUS-biopsy with 14 cores was employed as the standard procedure. Cognitive fusion biopsies were performed under sedoanalgesia. SonoSite Turbo M ultrasonography device (SonoSite Ltd.) coupled with its ICTx transducer (bandwidth of 8–5 MHz and 11 mm broadband tightly curved array) was

used during transrectal biopsy procedures. For antibiotic prophylaxis, all patients took ceftriaxone (1 g, IV, on the morning of the biopsy) and ciprofloxacin (500 mg, BID, per oral, starting two days before the procedure and continuing four days thereafter). Standard cores were taken first. Afterwards additional cores (mean, 3.2 cores; range, 1.4–8 cores) were taken from the MRI-defined cancer suspicious regions. Targeted cores were potted separately.

MRI-guided in-bore biopsy technique

In-bore biopsy was performed in a separate session within an average of 17.2 days (range, 3–30 days) after the initial diagnostic mp-MRI acquisition. It was conducted under local anesthesia within the MRI bore using a commercial platform (DynaTRIM, Invivo Corporation), after fusing the prior mp-MRI demonstrating cancer suspicious lesions with a contemporaneous MRI to confirm biopsy needle localization (Fig. 1). Transrectal route was employed and every cancer suspicious lesion was sampled; systematic sampling was not performed. One to five samples (mean, 3.4) were taken per

cancer suspicious region, depending on the certainty of correct needle position within the lesion and the size of the lesion. A maximum of three different cancer suspicious regions (mean, 1.5; range, 1–3) were biopsied per patient.

Antibiotic prophylaxis was employed in the same manner as cognitive fusion biopsies. Prostate biopsies were performed with the patient in the prone position, with the coil elements positioned beneath and on the back of the patient. The magnetic resonance-visible needle guide was inserted into the rectum and connected to the arm of the biopsy device. The arm enables the needle guide to be rotated, moved forward and backward, and adjusted in height. The needle guide was then directed to the defined cancer suspicious regions within the prostate. After correct alignment, the needle guide was fixed in position for obtaining tissue samples with an 18-gauge, fully automatic, core-needle, double-shot biopsy gun with needle length of 150 mm and tissue core sampling length of 17 mm. In-bore biopsies were conducted by the radiologist who reviewed the mp-MRI images. He has been working with mp-MRI of the prostate for 2.5 years.

Correlation of MRI and biopsy

Biopsy specimens were immediately fixed in formalin and subsequently underwent routine histopathologic evaluation by a dedicated urogenital histopathologist with 10 years of experience. When prostatectomy was not performed, clinical significance of prostate cancer was defined by: 1) a PSA >10 ng/mL and a PSA density >0.15 ng/mL per mL; 2) clinical stage \geq T2b; 3) a Gleason grade 4 or 5 within the biopsy specimen; 4) >2 positive cores with >30% involvement in each core. For in-bore biopsies the criteria for clinical significance were as follows; 1) a PSA >10 ng/mL and a PSA density >0.15 ng/mL per mL; 2) clinical stage \geq T2b; 3) a Gleason grade 4 or 5 within the biopsy specimen; 4) a total cancer-core length \geq 10 mm (8–11). In case of performed prostatectomy, prostate cancer was considered clinically significant when prostate cancer volume was \geq 0.5 mL or a stage \geq pT3 or a Gleason grade 4 or 5 was present (12, 13).

Statistical analysis

Patient characteristics (age, family history), clinical parameters (digital rectal examination findings, serum PSA value,

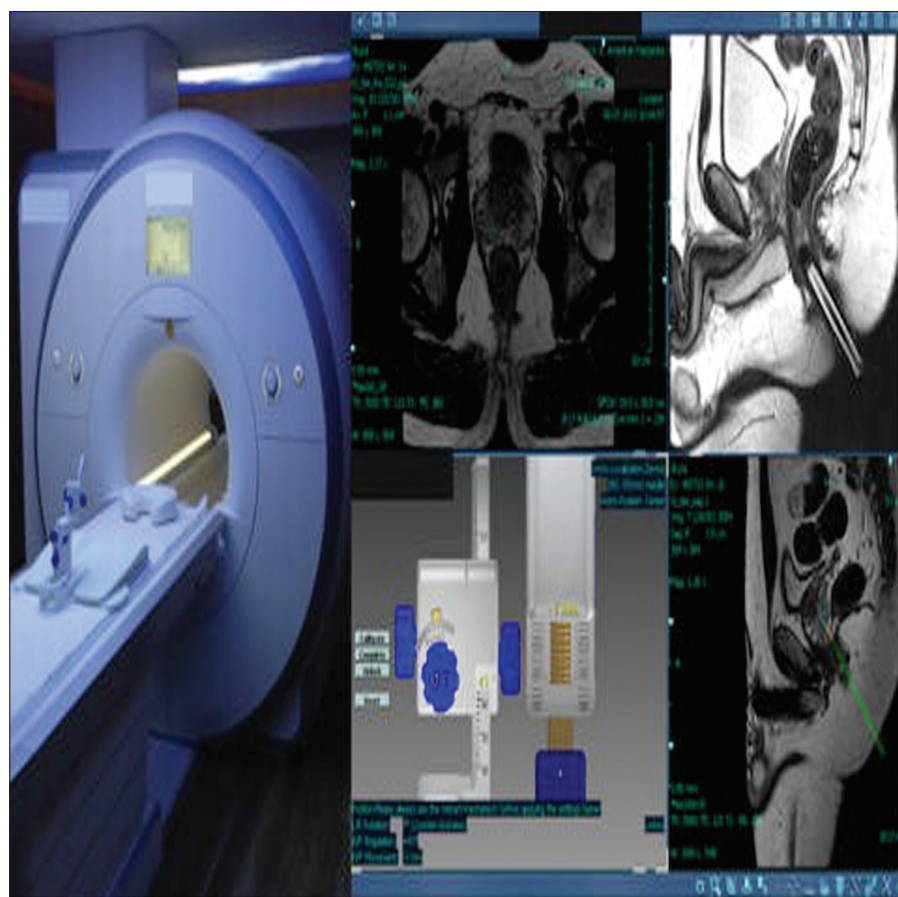


Figure 1. The hardware and software used during in-bore MRI-guided transrectal prostate biopsies.

mp-MRI findings, prior negative biopsy status), histopathologic findings in the biopsy specimens, and the clinical outcome were analyzed. Statistical calculations were performed with the t test, Fisher's exact test, chi-square test, and one way ANOVA test which were provided by commercially available software (SPSS version 20, IBM Corp.). A *P* value of < 0.05 was considered as statistically significant.

Results

A total of 100 biopsy-naive men without a palpable abnormality suggesting \geq cT3 disease, underwent their initial transrectal prostate biopsy in our hospital (TRUS-guided [n=37], cognitive fusion [n=49], and in-bore [n=14]). Mean age, serum PSA value, and prostate size did not differ significantly among the study groups (Table 1).

In the TRUS-guided biopsy group, patient-based tumor detection rate was 51.3% (19/37), while the same ratio was 55.1% (27/49) and 71.4% (10/14) in the cognitive fusion and in-bore biopsy groups, respectively (*P* = 0.429). The incidence of clinically significant prostate cancer, based on clinical and TRUS-biopsy findings, was 69.1% (12/19), 70.3% (19/27), and 90% (9/10) in the TRUS-guided, cognitive fusion, and in-bore biopsy groups, respectively (*P* = 0.31) (Table 2). Similarly, the detection rate of clinically significant disease based on clinical criteria were not significantly different between the groups (TRUS-guided vs. cognitive fusion-guided, TRUS-guided vs. in-bore, cognitive fusion-guided vs. in-bore; Tables 3–5).

In the TRUS-guided biopsy group, those who were diagnosed with prostate cancer were offered active surveillance (n=6, 31.5%), radiotherapy (n=3, 15.7%), and radical prostatectomy (n=10, 52.6%). Of patients who underwent radical prostatectomy in our hospital, all except one (87.5%, 7/8) had significant prostate cancer according to the histopathologic findings in the prostatectomy specimen.

Based on the whole prostate scores, prostates in the cognitive fusion group were categorized as PI-RADS 2 (n=3, 6.1%), PI-RADS 3 (n=9, 18.3%), PI-RADS 4 (n=8, 16.3%), and PI-RADS 5 (n=29, 59.1%). None in the PI-RADS 2 subcategory were found to harbor prostate cancer, while 22.2% (2/9), 50% (4/8), and 72% (21/29) of patients in PI-RADS 3, 4, and 5 subcategory, respectively were diagnosed with prostate cancer after the histopathologic examination of the cognitive fusion biopsy

specimens. Of note, clinically significant prostate cancer ratio increased as the PI-RADS score got higher; 50% (1/2) in PI-RADS 3, 75% (3/4) in PI-RADS 4, and 76.1% (16/21) in PI-RADS 5.

Active surveillance (n=6, 22.2%), radiotherapy (n=3, 11.1%) and radical prostatectomy (n=18, 66.6%) were the advised treatment options based on the clinical and pathologic variables in the cognitive biopsy group. Among those who were operated in our hospital (n=16), all except one (93.7%,

15/16) had significant prostate cancer according to the histopathologic assessment of the prostatectomy specimen.

In the in-bore biopsy group, the majority of the patients (12/14, 85.7%) were scored as PI-RADS 5, while the remaining two patients were classified as PI-RADS 4 in terms of the overall radiologic impression of the prostate gland. In the in-bore group, patients who had prostate cancer were managed by radical prostatectomy (n=7, 70%), radiotherapy (n=2, 20%), and active surveil-

Table 1. Patient characteristics and comparison between patients biopsied by different techniques

	TRUS-guided (n=37)	Cognitive fusion (n=49)	In-bore (n=14)	<i>P</i>
Patient age (years)	62.3±7.03	60.4±8.4	61.7±9.1	0.544
Serum PSA value (ng/mL)	7.6±4.6	5.9±2.5	5.4±1.6	0.120
Prostate size on TRUS (g)	48.4±24.1	49.1±18.6	45.1±33.6	0.850

Data are presented as mean±standard deviation.

Table 2. Diagnostic yield with different types of biopsy, triple comparisons

	TRUS-guided n (%)	Cognitive fusion n (%)	In-bore n (%)	<i>P</i>
Prostate cancer diagnosis	19 (51.3)	27 (55.1)	10 (71.4)	0.429
Clinically significant prostate cancer based on clinical criteria	12 (69.1)	19 (70.3)	9 (90)	0.31
Clinically significant prostate cancer based on prostatectomy histopathology*	7 (87.5)	15 (93.7)	7 (100)	NA

*Those with available histologic data.

Table 3. Diagnostic yield in TRUS-guided vs. cognitive fusion biopsy

	TRUS-guided n (%)	Cognitive fusion n (%)	<i>P</i>
Prostate cancer diagnosis	19 (51.3)	27 (55.1)	0.828
Clinically significant prostate cancer based on clinical criteria	12 (69.1)	19 (70.3)	0.751
Clinically significant prostate cancer based on prostatectomy histopathology*	7 (87.5)	15 (93.7)	1.0

*Those with available histologic data.

Table 4. Diagnostic yield in TRUS-guided vs. in-bore biopsy

	TRUS-guided n (%)	In-bore n (%)	<i>P</i>
Prostate cancer diagnosis	19 (51.3)	10 (71.4)	0.224
Clinically significant prostate cancer based on clinical criteria	12 (69.1)	9 (90)	0.2
Clinically significant prostate cancer based on prostatectomy histopathology*	7 (87.5)	7 (100)	1.0

*Those with available histologic data.

Table 5. Diagnostic yield in cognitive fusion vs. in-bore biopsy

	Cognitive fusion n (%)	In-bore n (%)	P
Prostate cancer diagnosis	27 (55.1)	10 (71.4)	0.362
Clinically significant prostate cancer based on clinical criteria	19 (70.3)	9 (90)	0.393
Clinically significant prostate cancer based on prostatectomy histopathology*	15 (93.7)	7 (100)	1.0

*Those with available histologic data.

lance (n=1, 10%). All operated patients in this subgroup had significant prostate cancer in terms of pathologic findings in the prostatectomy specimen.

Discussion

Despite the widespread utility and acceptance of image-guided biopsy protocols after negative TRUS-guided biopsies (14–16), data is relatively scarce about the actual role of mp-MRI-guided prostate biopsies in biopsy-naïve patients. In our study, we tried to investigate if MRI-guidance via cognitive fusion or in-bore real-time targeting could increase the overall and clinically significant cancer detection rate in the initial biopsies of those men without DRE findings suggestive of locally advanced disease ($\geq cT3$). In the TRUS-guided group 51.3% of patients were diagnosed with prostate cancer, while 55.1% and 71.4% of patients in the cognitive fusion and in-bore biopsy groups, respectively, were found to have prostate cancer. Similarly, clinically significant prostate cancer (based on clinical criteria) was detected in 69.1%, 70.3%, and 90% of the men in TRUS-guided, cognitive fusion, and in-bore biopsy groups, respectively. Although the ratios were higher in the image-guided biopsy groups, the differences were not statistically significant.

Delongchamps et al. (17) also examined the use of prebiopsy mp-MRI in 391 consecutive, biopsy-naïve patients, and reported a cancer detection rate of 45% using systematic biopsy and 47% using targeted biopsy. Targeted biopsy was significantly better at detecting high Gleason score (≥ 7) cancer detecting an additional 17 high-grade cancers missed by systematic biopsy. Another similar study assessed the difference between targeted and systematic cores but they specifically focused on the percentage of clinically significant disease, defined as any cancer core length >5 mm or any Gleason pattern >3 (18). In their study, the targeted approach detect-

ed cancer in 236 of 555 men (43%) with the standard approach. Thirteen clinically significant cancers were missed with a targeted approach alone, and 12 significant cancers were missed with a standard approach. On the other hand, insignificant cancer was detected in 53 of 55 men (96.3%) in the standard approach and in no men using the targeted approach. Our cancer detection rates seem to be higher than those reported rates in the literature and this can be explained by our small sample sizes and the possible highly selected nature of the investigated patient population.

Another interesting finding we observed in our study was the correlation between, MRI-based suspicion level (PI-RADS scoring system) and the presence of an underlying clinically significant prostate cancer. Although the numbers are small in each subcategory and therefore a powerful statistical calculation is not possible, as the overall PI-RADS score increased the probability of diagnosing prostate cancer and discovering a clinically significant cancer got higher in our series. Junker et al. (19) evaluated PI-RADS for classifying mp-MRI findings using whole-mount step-section slides as the reference standard. When all single modality scores were combined, a substantially high discriminative ability of prostate cancer detection (AUC, 0.97; 95% CI, 0.95–0.99) was achieved. Additionally, no high-grade cancer (Gleason >7) was present at PI-RADS scores <4 and no Gleason 6 disease at a PI-RADS score of 5.

In our cohort, patients who underwent radical prostatectomy after mp-MRI targeted biopsies tended to have more clinically significant disease. Histopathology of the prostatectomy specimen detected clinically significant prostate cancer in 87.5% of patients in the TRUS-guided biopsy group. On the other hand, the same proportion was 93.7% and 100% in those who were managed by radical prostatectomy after the disease was detected by cognitive fusion

or in-bore biopsy, respectively. Although the detection rate of clinically significant disease was not significantly different between the groups, it is evident that there is a trend towards improved diagnostic efficiency with the adoption of image-guided sampling techniques. Perhaps, with a larger patient population or prospective randomization into all available biopsy techniques, including cognitive fusion, it would have been possible to achieve more solid outcomes in favor of MRI-guided prostate biopsies.

Our study has several limitations. Retrospective design with its inherent biases is a major concern. Although there were no significant differences between the study groups in terms of age, PSA level, and prostate size, the management algorithm was not homogenous. Moreover, the indications of mp-MRI and image-guided prostate sampling were not consolidated. Therefore selection biases should be taken into consideration. Also, not all patients were managed by radical prostatectomy and the definition of clinically significant prostate cancer was restricted to clinical parameters and TRUS-biopsy findings in the majority of the patients. Other limitations included the relatively low sample size and the use of PI-RADS version 1 for image interpretation instead of version 2 (which is currently pending to be formally announced).

In conclusion, mp-MRI guidance did not significantly increase the diagnostic yield in the initial set of transrectal prostate biopsies in our cohort. Guidance by mp-MRI may be offered as a more efficient approach after multiple negative biopsies and in detecting tumoral foci that might be overlooked during TRUS-guided biopsies because of their location, multiplicity, and size.

Conflict of interest disclosure

The authors declared no conflicts of interest.

References

1. Welch HG, Fisher ES, Gottlieb DJ, Barry MJ. Detection of prostate cancer via biopsy in the Medicare-SEER population during the PSA era. *J Natl Cancer Inst* 2007; 99:1395–1400. [CrossRef]
2. Hodge KK, McNeal JE, Terris MK, Stamey TA. Random systematic versus directed ultrasound guided transrectal core biopsies of the prostate. *J Urol* 1989; 142:71–75.
3. Haas GP, Delongchamps N, Brawley OW, Wang CY, de la Roza G. The worldwide epidemiology of prostate cancer: perspectives from autopsy studies. *Can J Urol* 2008; 15:3866–3871.
4. Barentsz JO, Richenberg J, Clements R, et al. ESUR prostate MR guidelines 2012. *Eur Radiol* 2012; 22:746–757. [CrossRef]

5. Hoeks CM, Schouten MG, Bomers JG, et al. Three-tesla magnetic resonance-guided prostate biopsy in men with increased prostate-specific antigen and repeated, negative, random, systematic, transrectal ultrasound biopsies: Detection of clinically significant prostate cancers. *Eur Urol* 2012; 62:902–909. [\[CrossRef\]](#)
6. Turkbey B, Mani H, Shah V, et al. Multiparametric 3T prostate magnetic resonance imaging to detect cancer: Histopathological correlation using prostatectomy specimens processed in customized magnetic resonance imaging based molds. *J Urol* 2011; 186:1818–1824. [\[CrossRef\]](#)
7. Bjurlin MA, Meng X, Le Nobin J, et al. Optimization of prostate biopsy: The role of magnetic resonance imaging targeted biopsy in detection, localization and risk assessment. *J Urol* 2014; 192:648–658. [\[CrossRef\]](#)
8. Ahmed HU, Hu Y, Carter T, et al. Characterizing clinically significant prostate cancer using template prostate mapping biopsy. *J Urol* 2011; 186:458–464. [\[CrossRef\]](#)
9. Bastian PJ, Mangold LA, Epstein JI, Partin AW. Characteristics of insignificant clinical T1c prostate tumors. A contemporary analysis. *Cancer* 2004; 101:2001–2005. [\[CrossRef\]](#)
10. D'Amico AV, Whittington R, Malkowicz SB, et al. Biochemical outcome after radical prostatectomy or external beam radiation therapy for patients with clinically localized prostate carcinoma in the prostate specific antigen era. *Cancer* 2002; 95:281–286. [\[CrossRef\]](#)
11. Partin AW, Yoo J, Carter HB, et al. The use of prostate specific antigen, clinical stage and Gleason score to predict pathological stage in men with localized prostate cancer. *J Urol* 1993; 150:110–114.
12. Gleason DF, Mellinger GT. Prediction of prognosis for prostatic adenocarcinoma by combined histological grading and clinical staging. *J Urol* 1974; 111:58–64.
13. Stamey TA, Freiha FS, McNeal JE, Redwine EA, Whittemore AS, Schmid HP. Localized prostate cancer: Relationship of tumor volume to clinical significance for treatment of prostate cancer. *Cancer* 1993; 71:933–938. [\[CrossRef\]](#)
14. Labanaris AP, Engelhard K, Zugor V, Nutzel R, Kuhn R. Prostate cancer detection using an extended prostate biopsy schema in combination with additional targeted cores from suspicious images in conventional and functional endorectal magnetic resonance imaging of the prostate. *Prostate Cancer Prostatic Dis* 2010; 13:65–70. [\[CrossRef\]](#)
15. Sonn GA, Chang E, Natarajan S, et al. Value of targeted prostate biopsy using magnetic resonance-ultrasound fusion in men with prior negative biopsy and elevated prostate-specific antigen. *Eur Urol* 2014; 65:809–815. [\[CrossRef\]](#)
16. Vourganti S, Rastinehad A, Yerram NK, et al. Multiparametric magnetic resonance imaging and ultrasound fusion biopsy detect prostate cancer in patients with prior negative transrectal ultrasound biopsies. *J Urol* 2012; 188:2152–2157. [\[CrossRef\]](#)
17. Delongchamps NB, Peyromaure M, Schull A, et al. Prebiopsy magnetic resonance imaging and prostate cancer detection: Comparison of random and targeted biopsies. *J Urol* 2013; 189:493–499. [\[CrossRef\]](#)
18. Haffner J, Lemaitre L, Puech P, et al. Role of magnetic resonance imaging before initial biopsy: Comparison of magnetic resonance imaging-targeted and systematic biopsy for significant prostate cancer detection. *BJU Int* 2011; 108:E171–178. [\[CrossRef\]](#)
19. Junker D, Quentin M, Nagele U, et al. Evaluation of the PI-RADS scoring system for MPMRI of the prostate: A whole-mount step-section analysis. *World J Urol* 2014. [Epub ahead of print] [\[CrossRef\]](#)