

Emergent stent-graft repair of a massive aortic pseudoaneurysm secondary to Behçet's disease in a child

Allison Dawson 

Giri M. Shivaram 

Sarah K. Baxter 

Eric J. Monroe 

Kevin S. H. Koo 

ABSTRACT

An 11-year-old male with vasculitis was found to have a large abdominal aortic pseudoaneurysm on diagnostic angiography. This report describes endovascular repair of the pseudoaneurysm by stent-graft exclusion. The existing literature surrounding this rare and potentially fatal condition is also reviewed.

Behçet's disease (BD) is a systemic vasculitis of small and large vessels. It most commonly manifests with oral and genital ulcerations, skin lesions, and uveitis; vascular, central nervous system and gastrointestinal involvement can also occur but are less common (1). Complications of arterial involvement result in high mortality, accounting for approximately 50% of all BD-related deaths in one series (2). Pulmonary artery aneurysm is the most common manifestation of arterial disease, but aortic aneurysm remains a major cause of death due to its high risk of catastrophic rupture (2). Surgical repair of BD with arterial involvement is associated with a high morbidity and complication rate, with recent reports now favoring endovascular repair (3). To our knowledge, this is the first reported case of stent-graft repair of BD-associated aortic pseudoaneurysm in a pediatric patient.

Technique

An 11-year-old boy was admitted with difficulty ambulating secondary to a suspected rheumatologic disorder. Approximately 6 months prior to admission, the patient was in his usual state of health when he developed waxing and waning aphthous ulcers. One month prior, he developed pain first in his left leg, then in his right leg and great toe, and finally in his thighs and lower back. At times, the patient described painful red macules on the dorsum of his right foot and right anterior lower leg. He also had 20 pounds of unintentional weight loss, attributed to his inability to ambulate and decreased appetite.

He initially sought care with an orthopedic surgery clinic at an outside institution, where magnetic resonance imaging (MRI) and plain radiography of his right foot were performed, showing nonspecific inflammatory changes consistent with myositis or sprain. Laboratory evaluation performed at this time was notable for an elevated erythrocyte sedimentation rate (ESR) of 104 mm/h (reference range <10 mm/h) and C-reactive protein (CRP) of 2.3 mg/dL (reference range <0.8 mg/dL). Rheumatology consultation was obtained, establishing a differential diagnosis of vasculitis, myositis, inflammatory bowel disease, sarcoidosis, malignancy, and ascorbic acid deficiency.

Further rheumatologic laboratory evaluation was notable for an elevated antistreptolysin O (ASO) titer of 1310 IU (reference range <200 IU). Antinuclear antibody (ANA), antineutrophil cytoplasmic antibodies (ANCA), anti-cyclic citrullinated peptide (anti-CCP), anti-myeloperoxidase (anti-MPO), anti-proteinase 3, creatine kinase (CK), rheumatoid factor and ferritin were all within normal range. Multiple hospital admissions were required to manage severe intermittent lower extremity pain with intravenous opioid analgesics. MRI of the lower extremities revealed persistent myositis in the anterior and lateral compartments of the right lower leg as well as in the intrinsic muscles of the right foot. No abnormal bone lesions were identified.

From the Departments of Physiology and Biology (A.D.) and Division of Interventional Radiology (G.M.S., E.J.M., K.S.H.K. ✉ kevin.koo@seattlechildrens.org) Department of Radiology, University of Washington School of Medicine, Missouri, USA; Department of Rheumatology (S.K.B.), Seattle Children's Hospital, University of Washington, Missouri, USA.

Received 30 January 2018; revision requested 26 February 2018; last revision received 29 March 2018; accepted 9 April 2018.

Published online 8 August 2018.

DOI 10.5152/dir.2018.18042

You may cite this article as: Dawson A, Shivaram GM, Baxter SK, Monroe EJ, Koo KSH. Emergent stent-graft repair of a massive aortic pseudoaneurysm secondary to Behçet's disease in a child. *Diagn Interv Radiol* 2018; 24:295-297.

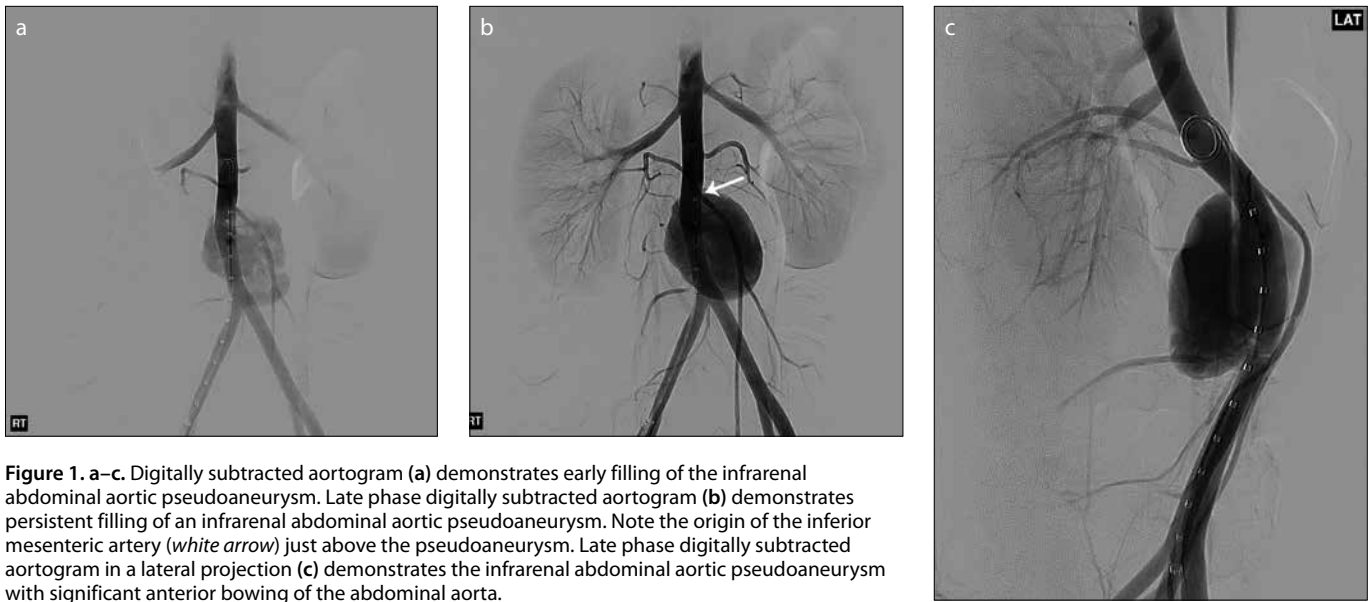


Figure 1. a–c. Digitally subtracted aortogram (a) demonstrates early filling of the infrarenal abdominal aortic pseudoaneurysm. Late phase digitally subtracted aortogram (b) demonstrates persistent filling of an infrarenal abdominal aortic pseudoaneurysm. Note the origin of the inferior mesenteric artery (white arrow) just above the pseudoaneurysm. Late phase digitally subtracted aortogram in a lateral projection (c) demonstrates the infrarenal abdominal aortic pseudoaneurysm with significant anterior bowing of the abdominal aorta.

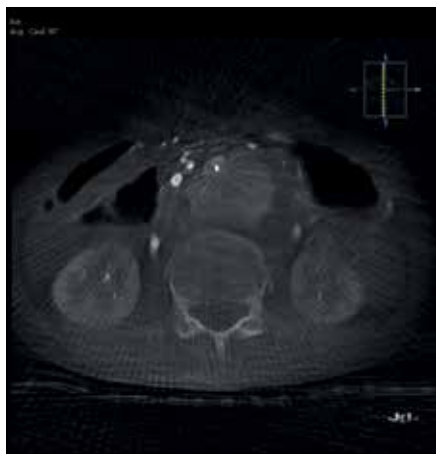


Figure 2. Cone-beam CT aortogram in axial plane, better demonstrates the extent of the pseudoaneurysm arising from the infrarenal abdominal aorta.

The patient was then referred to interventional radiology at our institution for diagnostic catheter mesenteric arteriography to evaluate for vasculitis. Via right femoral

artery access, biplane digital subtraction abdominal aortography was performed, demonstrating a 4.7×3.5×2.9 cm pseudoaneurysm originating from the posterior wall of the infrarenal abdominal aorta (Fig. 1). Associated compression and anterior bowing of the aorta was seen, better demonstrated on cone-beam computed tomography (CT) aortogram with postprocessing three-dimensional reconstruction (Fig. 2).

An intact superior mesenteric artery (SMA) to inferior mesenteric artery (IMA) collateral (Arc of Rioloan) was identified. Lower abdominal aortogram confirmed a wide defect in the posterior wall of the abdominal aorta, with the superior margin of the defect just below the IMA.

Following intraprocedural consultation with the surgery service to discuss possible open operative repair, endovascular treatment was pursued. The right femoral artery sheath was exchanged for an 8 F vascular sheath, through which a 10×39 mm balloon-expandable stent-graft (Viabahn VBX, W.L. Gore & Associates) was deployed in the infrarenal abdominal aorta extending from the origin of the IMA to the terminal portion of the aorta approximately 1 cm superior to the aortic bifurcation. Repeat aortography was performed demonstrating mild persistent filling of the pseudoaneurysm superiorly, as well as persistent opacification of the IMA. An additional overlapping 11×39 mm balloon-expandable stent-graft (Viabahn VBX, W.L. Gore & Associates) was deployed superiorly, extending to the origins of the L2 lumbar arteries (Fig. 3a).

Completion aortography demonstrated no further opacification of the aortic pseudoaneurysm (Fig. 3b). The right femoral sheath was removed and hemostasis achieved by deploying an 8 F vascular closure device (Angio-Seal VIP, Terumo Interventional Systems).

The patient was started on a continuous intravenous infusion of heparin (eventually transitioned to enoxaparin), clopidogrel, aspirin, and a 3-day methylprednisone burst followed by maintenance high-dose prednisone. His abdominal pain and appetite had significantly improved by postprocedure day one. Subsequent echocardiography, MRI, magnetic resonance angiography, carotid ultrasonography and CT angiography of the chest, abdomen and pelvis were all performed without evidence of other vascular abnormalities.

Shortly after discharge, monthly infliximab infusions were started along with methotrexate. At 2 months postprocedure, the patient's clinical symptoms had dramatically improved with no imaging evidence of pseudoaneurysm recurrence. His inflammatory markers normalized with ESR at 6 mm/h and CRP at <0.8 mg/dL.

Discussion

Behçet's disease (BD), first discovered in 1937 by dermatologist Hulusi Behçet, is a small and large vessel systemic autoimmune vasculitis. Mean age of onset of BD is 30 years, with pediatric onset before the age of 16 in 4%–26% of cases (4). Vasculo-BD, or BD with vascular complications or

Main points

- Behçet's disease (BD) is a systemic vasculitis of small and large vessels with arterial involvement accounting for high morbidity and mortality.
- Aortic involvement requires urgent repair with endovascular techniques preferred over surgery given surgical complications and a high incidence of recurrence.
- Stent-graft repair of BD-associated aortic pseudoaneurysms, while described in adults, can be a safe treatment option in children.

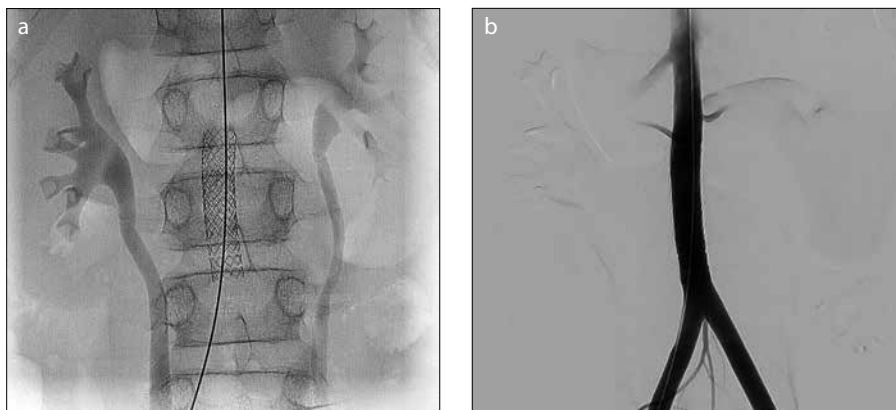


Figure 3. a, b. Static frontal fluoroscopic image (a) shows the overlapping balloon expandable stent-grafts (Viabahn VBX, W.L. Gore & Associates) deployed across the posterior aortic defect, as well as the origin of the inferior mesenteric artery. Completion frontal aortogram after stent deployment (b) demonstrates no further opacification of the large infrarenal aortic pseudoaneurysm.

vascular predominant involvement is characterized by venous thrombosis, arterial occlusion and aneurysm formation and has been reported to occur in 4.4%–26.5% of adult BD patients and 5%–20% of pediatric BD patients (4).

Vasculo-BD most frequently affects the venous system, usually manifesting as deep venous thrombosis (DVT) of the legs, with venous thrombosis of the superior vena cava (SVC), inferior vena cava, or hepatic veins also reported, leading to SVC syndrome or Budd-Chiari syndrome (1). Arterial complications are reported in 1%–7% of BD patients with development of true or false aneurysms in great vessels (1). In the adult population, there is high mortality for arterial involvement, accounting for approximately 50% of all BD-related deaths in one series (2). While pulmonary artery aneurysm is more common, aortic aneurysms remain a major cause of death (2, 3). Aortic complications are rare in children, however, with only one published case of a pediatric patient with vasculo-BD complicated by an aortic pseudoaneurysm, which was subsequently treated with open surgical repair (5).

Mortality of open surgical repair for BD aortic aneurysms is high, ranging from 10%–30% and recurrent pseudoaneurysm formation occurs at anastomotic sites in 10%–50% of patients (6). Given this, Liu et al. (6) and others have advocated endovascular repair over open surgical repair, performed in combination with systemic immunosuppressive therapy. While endovascular repair of aortic pseudoaneurysms in BD have been well described in adults, there have been no reports on the use of

stent-grafts for this indication in children.

The use of balloon-expandable stent-grafts in children has been previously reported for treatment of traumatic aortic injury (TAI). Goldstein et al. (7) reported on a series of 4 pediatric patients who underwent placement of an endovascular stent-graft for TAI with no reported long-term complications at a median follow up of 24 months.

In addition to allowing for more precise placement at initial deployment, balloon-expandable stent-grafts can be overdilated at a future procedure to accommodate normal growth of a child's aorta. For example, the 11×39 mm balloon-expandable stent-graft (Viabahn VBX, W.L. Gore & Associates) used in our patient can be dilated up to a maximum stent diameter of 13 mm (or 16 mm in *in vitro* studies) (8). Nidorf et al. (9) conducted a two-dimensional echocardiographic study in 196 children (aged 6 days to 18 years), reporting that great vessels grow at a predictable rate after birth, reaching 50% of adult dimensions at birth, 75% by 5 years and 90% by 12 years (9). Therefore, it is possible that our 11-year-old patient may need only minimal, if any, overdilation of his aortic stent-graft at a future procedure.

Pseudoaneurysm recurrence remains a concern with rates reported between 14.3%–22.2%, though this may be lowered by use of immunosuppressive and anti-inflammatory therapy (3, 6). To this day, our patient continues to receive monthly infliximab and methylprednisolone infusions with plans for imaging follow-up every 6 months to monitor for possible recurrence.

In conclusion, BD-associated aortic pseudoaneurysms, while rare, have high rates of morbidity and mortality. Recent reports favor endovascular repair over traditional open surgical repair, performed in conjunction with administration of systemic immunosuppressive and anti-inflammatory therapy. This report describes a case of BD-associated abdominal aortic pseudoaneurysm in an 11-year-old boy treated with endovascular stent-graft placement. The procedure was uncomplicated, successful and well-tolerated, suggesting that endovascular stent-grafting of the aorta can be a safe treatment option for pseudoaneurysm repair in the pediatric population.

Conflicts of interest disclosure

The authors declared no conflicts of interest.

References

1. Calamia KT, Schirmer M, Melikoglu M. Major vessel involvement in Behçet's disease: an update. *Curr Opin Rheumatol* 2011; 23:24–31. [\[CrossRef\]](#)
2. Kural-Seyahi E, Fresko I, Seyahi N, et al. The long-term mortality and morbidity of Behçet syndrome: a 2-decade outcome survey of 387 patients followed at a dedicated center. *Medicine (Baltimore)* 2003; 82:60–76. [\[CrossRef\]](#)
3. Kim SW, Lee DY, Kim MD, et al. Outcomes of endovascular treatment for aortic pseudoaneurysm in Behçet's disease. *J Vasc Surg* 2014; 59:608–614. [\[CrossRef\]](#)
4. Kone-Paut I. Behçet's disease in children, an overview. *Pediatr Rheumatol Online J* 2016; 14:10. [\[CrossRef\]](#)
5. Kutay V, Yakut C, Ekim H. Rupture of the abdominal aorta in a 13-year-old girl secondary to Behçet disease: a case report. *J Vasc Surg* 2004; 39:901–902. [\[CrossRef\]](#)
6. Liu C-W, Ye W, Liu B, Zeng R, Wu W, Dake MD. Endovascular treatment of aortic pseudoaneurysm in Behçet disease. *J Vasc Surg* 2009; 50:1025–1030. [\[CrossRef\]](#)
7. Goldstein BH, Hirsch R, Zussman ME, et al. Percutaneous balloon-expandable covered stent implantation for treatment of traumatic aortic injury in children and adolescents. *Am J Cardiol* 2012; 110:1541–1545. [\[CrossRef\]](#)
8. W. L. Gore & Associates, Inc. Instructions for Use for GORE® VIABAHN® VBX Balloon Expandable Endoprosthesis. Flagstaff, AZ: Gore Associates, 2016; 1–13.
9. Nidorf SM, Picard MH, Triulzi MO, et al. New perspectives in the assessment of cardiac chamber dimensions during development and adulthood. *J Am Coll Cardiol* 1992; 19:983–988. [\[CrossRef\]](#)