

# Value of follow-up angiography: additional interventions in patients undergoing catheter-directed thrombolysis for massive and submassive pulmonary embolism

Osman Ahmed 

Nhi Vo 

Mikin V. Patel 

Nerina DiSomma 

Merve Özen 

Bülent Arslan 

## PURPOSE

Catheter-directed thrombolysis (CDT) is an emerging, minimally invasive treatment for patients with massive and submassive pulmonary embolism (PE). The value of follow-up pulmonary angiography for evaluating improvement after CDT is limited by a paucity of large studies assessing its utility and role for additional intervention. The purpose of our study was to assess the role of next-day pulmonary angiography for CDT in patients with acute massive and submassive PE undergoing continuous pulmonary arterial pressure monitoring, and secondarily, determine factors that are correlated with a need for further therapy.

## METHODS

Patients who underwent CDT from 2006 to 2016 for massive and submassive PE were reviewed. Patient demographics, comorbidities, preprocedural lab results, noninvasive hemodynamic studies, and technical variables were recorded. Among patients receiving next-day angiography, those requiring further therapy, defined as continued CDT beyond the standard 24 hours (with or without catheter repositioning or exchange) and/or mechanical or suction thrombectomy were contrasted with those not requiring additional therapy to assess for the role of angiography and patient factors that correlate with need for further therapy.

## RESULTS

Thirty-two patients underwent CDT for massive (n=14) and submassive (n=18) PE. Eighteen (56.3%) were male, 14 (43.7%) were Caucasian, 18 (56.3%) were African-American, with a mean age of 66.2 years (range, 26–87 years). Of the 27 (84.4%) patients that underwent next-day pulmonary angiography, 16 (59.3%) did not require additional therapy and 11 (40.7%) did require additional therapy. Additional therapy included extended CDT beyond 24 hours (n=4), mechanical/suction thrombectomy (n=5), or both extended CDT and mechanical/suction thrombectomy (n=2). Younger age (50.1 vs. 62.2 years,  $P = 0.039$ ) was correlated with a need for further therapy. Initial (40.7 vs. 34.8 mmHg,  $P = 0.248$ ), next-day (31.5 vs. 26.3 mmHg,  $P = 0.259$ ), and interval change (4.6 vs. 8.0 mmHg,  $P = 0.669$ ) in pulmonary artery pressures were not statistically significant between patient subsets. Preprocedural right ventricular/left ventricular ratio (RV/LV) also did not differ significantly (1.74 vs. 1.75,  $P = 0.961$ ). Thirty-day mortality was comparable (2 vs. 1,  $P = 0.332$ ).

## CONCLUSION

Next-day pulmonary angiography is a useful method to identify patients needing additional therapy including extended CDT and/or mechanical or suction thrombectomy in acute PE management. Pulmonary arterial pressures and preprocedural RV/LV ratios were not found to be predictive of those requiring further intervention.

From the Division of Interventional Radiology, Department of Radiology (O.A. ✉ [Osman1423@gmail.com](mailto:Osman1423@gmail.com), N.V., N.D., M.Ö., B.A.), Rush University School of Medicine, Chicago, IL, USA; Division of Interventional Radiology, Department of Radiology (M.V.P.), Northwestern Medicine, Chicago, IL, USA.

Received 5 April 2018; revision requested 10 May 2018; last revision received 22 November 2018; accepted 4 December 2018.

Published online 23 May 2019.

DOI 10.5152/dir.2019.18142

**A**cute pulmonary embolism (PE) is a life-threatening condition accounting for approximately 300 000 deaths annually (1). With an aging population, the overall incidence of PE is increasing to nearly 112 cases per 100 000 (2). Massive PE, defined as right ventricular (RV) dysfunction with sustained hypotension, has been associated with a mortality rate of 25%–65% (1, 3). Management options beyond therapeutic anticoagulation for acute massive and submassive PE (RV dysfunction in the absence of hypotension) include the administration of a systemic thrombolytic agent. When administered intravenously, thrombolytics are associated with a 9.2% risk of major hemorrhagic complication, including a 1.5% risk of intracranial hemorrhage (3).

You may cite this article as: Ahmed O, Vo N, Patel MV, DiSomma N, Özen M, Arslan B. Value of follow-up angiography: additional interventions in patients undergoing catheter-directed thrombolysis for massive and submassive pulmonary embolism. *Diagn Interv Radiol* 2019; 25:298–303.

Catheter-directed thrombolysis (CDT) is an emerging, minimally invasive alternative treatment for patients with massive and submassive PE. The Society of Interventional Radiology (SIR) supports the use of catheter-directed therapy or thrombolysis for patients with massive (high-risk) PE involving the proximal pulmonary arterial vasculature and encourages its investigative use in submassive (intermediate-risk) PE (3). Localized, direct administration of thrombolytic agents in CDT has been shown to decrease right heart strain and improve RV function with low rates of hemorrhagic complication (1, 3–5). Clinical improvement, defined as a reduction in pulmonary arterial pressure and normalized right ventricular to left ventricular ratio (RV/LV), is typically achieved within 24 hours of CDT infusion. Additional therapy including continued CDT, mechanical fragmentation, or suction thrombectomy may be necessary in a subset of patients with large clot burden and unresolved elevated pulmonary arterial pressures. Variables associated with continued CDT and/or additional mechanical endovascular interventions are not well described in the literature. Follow-up pulmonary angiography after 24 hours of lysis may help to determine residual clot burden, the need for catheter repositioning, and identify patients requiring continued therapy and/or additional interventions. The aim of this study was to assess the utility of follow-up pulmonary angiography for CDT in patients with acute massive and submassive PE undergoing continuous pulmonary arterial pressure monitoring and to determine any factors that may be correlated with further therapy.

#### Main points

- Catheter-directed thrombolysis (CDT) is an evolving therapeutic option for patients with acute massive or submassive pulmonary embolism (PE); however, assessments of therapeutic effect are not standardized.
- The use of pulmonary angiography following initiation of CDT, unlike other imaging modalities, allows for real-time evaluation of persistent clot burden and the efficacy of adjunctive therapy.
- This study showed that compared with both initial and next-day pulmonary artery pressure and RV/LV ratios, follow-up pulmonary angiography was predictive and helped identify patients needing extended CDT and/or additional interventions.

## Methods

This study was performed following institutional review board approval with a waiver of consent (protocol number 16031403). A retrospective review was performed on 164 patients with suspected acute PE referred for intervention over a 10-year period (2006–2016) at a tertiary care academic institution. Referral to interventional radiology for pulmonary angiography and possible intervention was determined following consultation request from the primary physician, which included both critical care and emergency medicine departments. Inclusion criteria were symptomatic acute proximal PE confirmed by contrast-enhanced computed tomography (CT) and RV/LV ratios  $\geq 0.9$ . Exclusion criteria were patients  $< 18$  years old and onset of symptoms  $> 14$  days. Of patients meeting criteria, a subset receiving CDT were identified from an “electronic medical record database (Epic)”. Massive and submassive PE were defined according to the American Heart Association guidelines (6).

Patients who received CDT returned the next day for follow-up pulmonary angiography to assess whether additional therapy, defined as continued CDT beyond the standard 24 hours (with or without catheter repositioning or exchange) and/or mechanical or suction thrombectomy, were necessary. Patients receiving additional therapy were stratified against their cohorts who did not. Follow-up pulmonary angiography after CDT was the standard of care at our institution. Due to this institutional practice and the retrospective nature of our study, a control group was not able to be obtained.

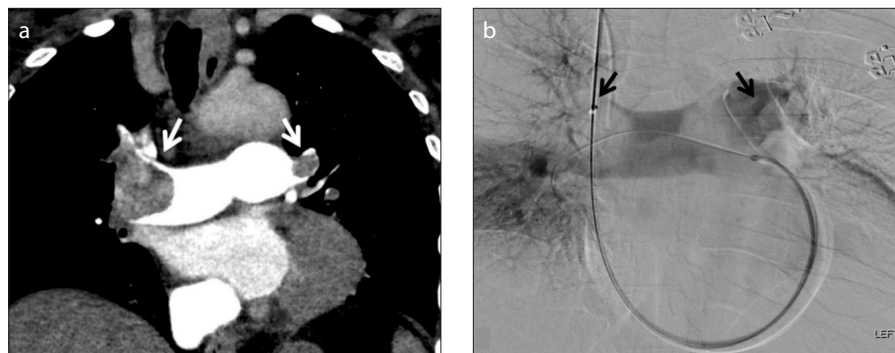
Patient demographics including comorbidities, preprocedural lab results, presence or absence of deep vein thrombosis (DVT)

at presentation, preprocedural noninvasive hemodynamic studies including RV size and pulmonary artery pressure as well as calculated Miller Index Scores to compare obstruction to pulmonary perfusion were recorded for these two patient subsets (Table 1). The GE Centricity® picture archiving and communication system (PACS) (GE Healthcare) was queried to assess technical variables such as access site, catheter positioning, catheter length, and infusion parameters (Table 2).

## Technique

Access was achieved using standard micropuncture technique under ultrasound guidance for all cases. In 26 of 32 cases, a 5 F angled catheter (Cook Medical) or 7 F “MONT” catheter (Cook Medical) was advanced under fluoroscopic guidance via femoral access and an inferior vena cogram was performed to confirm patency. Transjugular access was performed in the remaining 6 cases with a 5 F angled catheter (Cook Medical). Transjugular approach on these patients was due to operator preference. Multi-sidehole catheters were directed across the right heart chambers into the main pulmonary artery where preprocedural pulmonary artery pressures were obtained and angiography was performed to evaluate clot location and burden (Fig. 1).

For massive PE patients, suction thrombectomy and/or fragmentation with a 5 or 6 F rotating pigtail catheter (Cook Medical) was performed prior to initiating CDT. In all surviving patients, 5 F Cragg-McNamara® infusion catheter(s) (Medtronic) were advanced and positioned within identified clot burden. TPA infusion was initiated and left overnight at a catheter combined rate of 0.5–1.5 mg/h. Heparin was also initiated at a combined rate of 250–600 units/h. For submassive PE patients, thrombolytic



**Figure 1. a, b.** Coronal reformat of chest CT angiogram demonstrating bilateral pulmonary emboli (a, white arrows). Pulmonary digital subtraction angiogram demonstrating bilateral pulmonary artery emboli (b, black arrows).

**Table 1.** Patient demographics, clinical data, and pre- and postprocedural pulmonary artery pressures stratified by the need for additional therapies as identified by follow-up pulmonary angiography for acute massive and submassive PE

	No additional therapy (n=16)	Additional therapy (n=11)	P
Mean age (years)	62.2±13.3	50.1±15.4	0.039
Sex ratio (M:F)	11:5	6:5	0.687
Ethnic ratio (Caucasian: African American)	7:9	5:6	1.000
Prior PE	3 (19)	2 (18)	1.000
Prior DVT	3 (19)	2 (18)	1.000
Past medical history			
Hypertension	8 (50)	5 (45)	1.000
Hyperlipidemia	5 (31)	3 (27)	1.000
Diabetes	3 (19)	1 (9)	0.624
CAD	2 (13)	1 (9)	1.000
Obesity (BMI >25 kg/m <sup>2</sup> )	7 (44)	9 (82)	0.109
Massive vs. submassive PE			
Massive PE	6 (38)	7 (64)	0.345
Submassive PE	10 (63)	4 (36)	
DVT on presentation	5 (31)	3 (27)	1.000
CT-PE dimensions (mm)			
RV diameter	46.54±7.5	44.93±4.9	0.538
LV diameter	27.97±6.5	26.29±3.9	0.452
RV/LV ratio	1.75±0.5	1.74±0.3	0.961
Miller index scores	20.1±3.0	22.0±4.4	0.219
Elevated troponin on presentation	7 (44)	6 (55)	0.873
Mean initial pulmonary pressure (mmHg)	34.8±10.9	40.7±13.1	0.248
Mean next-day pulmonary pressure (mmHg)	26.3±12.8	31.5±7.6	0.259
Mean interval change in pulmonary pressure (mmHg)	8.0±13.0	4.6±27.1	0.669

Data are presented as mean±standard deviation or n (%).  
PE, pulmonary embolism; M, male; F, female; DVT, deep vein thrombosis; CAD, coronary artery disease; BMI, body mass index; CT-PE, computed tomography pulmonary embolus study; RV, right ventricle; LV, left ventricle.

therapy was initiated without mechanical thrombectomy.

Utilizing Society of Interventional Radiology reporting standards for the treatment of PE, minor and major complications were recorded (7). Minor complications were defined as those requiring nominal or no therapy with no consequence including overnight observational admission, mild contrast reactions, transient arrhythmia, catheter-related site infections, and small

hematomas not requiring transfusion. Major complications were broadly defined as those requiring therapies with <48 hours of hospital admission, major therapy, unplanned escalation in the level of care, or prolonged hospitalization (>48 hours), including anaphylactic reactions to contrast dye, right heart block, worsening hypoxia, increased pulmonary hypertension, worsening hemodynamic instability, cardiopulmonary structural perforation, hemorrhage

requiring transfusion, any irreversible sequelae, and/or death.

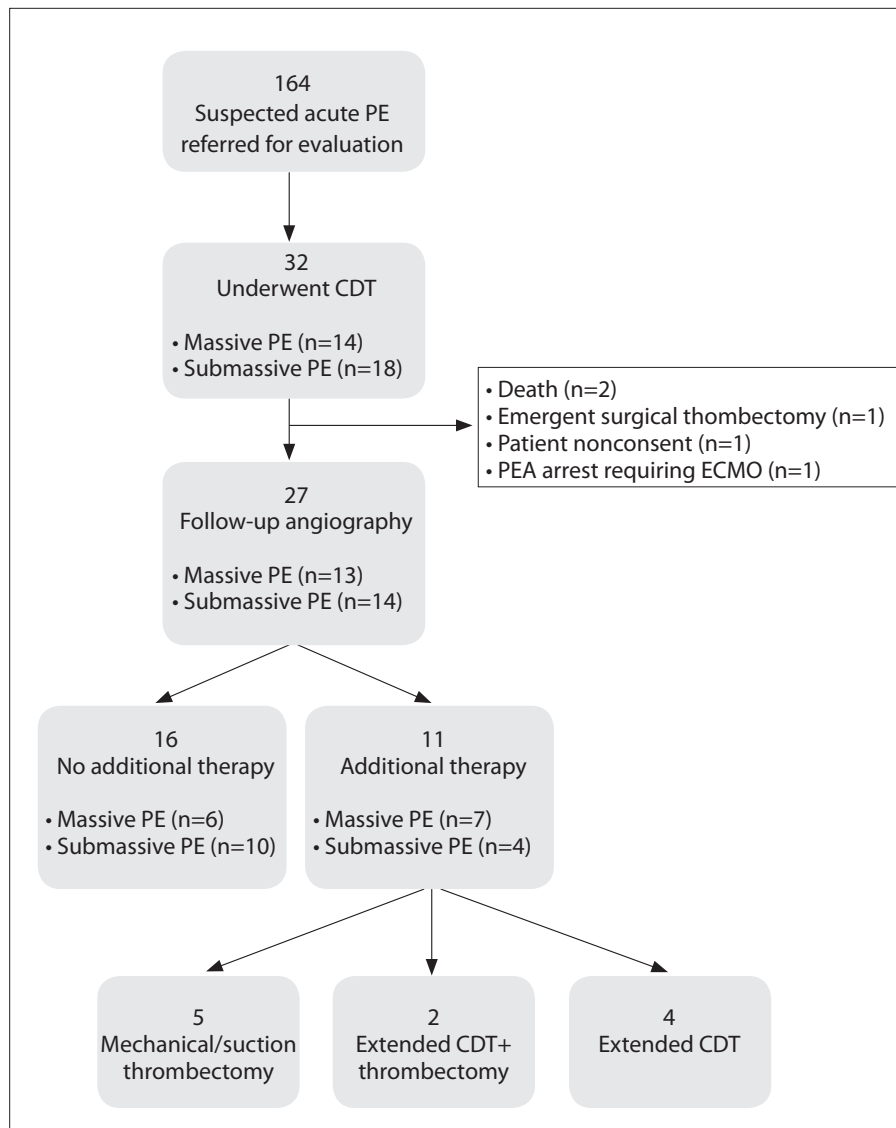
### Statistical analysis

Patients were divided into groups based on need for additional therapy on follow-up angiography post-CDT. Categorical variables were compared using Pearson chi square/Continuity correction (Yates) if the expected count is less than 20% and Fisher's exact test if the expected count is greater than or equal to 20%. Continuous variables were compared using two sample Student's t-test. A P value of < 0.05 was considered to be statistically significant. Results are reported as mean±standard deviation. All statistical analysis was performed using the STATA Statistics/Data Analysis software package (v14.2 1985-2015; StataCorp, LP).

### Results

Of 164 patients referred for possible CDT, 32 (19.5%) underwent CDT for massive (n=14) and submassive (n=18) PE. Eighteen (56.3%) were male, 14 (43.7%) were Caucasian, 18 (56.3%) were African-American, and mean age was 66.2 years (range, 26–87 years). Twenty-seven of the 32 patients (84.4%, massive [n=13], submassive [n=14]) returned the next day for follow-up pulmonary angiography (Fig. 2). The reasons for not receiving follow-up angiography were death (n=2), pulseless electrical activity (PEA) arrest requiring extracorporeal membrane oxygenation (ECMO) support (n=1), need for emergent surgical thrombectomy (n=1), and patient nonconsent (n=1) (Fig. 2). In patients who received follow-up angiography, imaging identified 11 (40.7%) patients as needing further therapy which included extended CDT beyond 24 hours (with or without catheter repositioning or exchange) and/or additional interventions including mechanical/suction thrombectomy (Fig. 2).

Of this cohort, five patients (45.5%) received only mechanical or suction thrombectomy in response to follow-up angiography findings. A total of six (54.5%) required CDT extension up to 48 hours (n=4) and 72 hours (n=2) due to residual thrombus burden visualized on angiography. Of these six patients, five (83.3%) either underwent catheter repositioning (n=2), exchange for increased infusion length (n=2), or exchange due to catheter occlusion (n=1). The remaining patient who underwent extended CDT did not require catheter repositioning or



**Figure 2.** Study algorithm. PE, pulmonary embolism; CDT, catheter-directed thrombolysis; PEA, pulseless electrical activity; ECMO, extracorporeal membrane oxygenation.

exchange. Of the patient subset receiving extended CDT, two (33.3%) also received mechanical or suction thrombectomy.

Despite angiographic identification of a subset of patients needing additional therapy, initial (40.7 vs. 34.8 mmHg,  $P=0.248$ ), next-day (31.5 vs. 26.3 mmHg,  $P=0.259$ ), and interval change (4.6 vs. 8.0 mmHg,  $P=0.669$ ) in pulmonary artery pressures were not statistically different between patient subsets that received further therapy ( $n=11$ ) and those that did not ( $n=16$ ) (Table 1). Preprocedural RV/LV ratio also did not differ significantly between these patient groups (1.74 vs. 1.75,  $P=0.961$ ) (Table 1).

After using Student t-tests for continuous and Pearson chi square/Yates or Fisher's ex-

act tests for categorical variables, younger age (50.1 vs. 62.2 years,  $P=0.039$ ) was the only variable correlated with a need for additional therapy. Other factors studied were not significant (Table 1). Technical variables associated with CDT stratified by the need for additional therapy did not show statistical significance between groups (Table 2).

Three complications occurred in patients receiving CDT during their hospital course; all of which occurred in patients undergoing additional therapy. These included two minor complications after follow-up angiography: a small groin hematoma ( $n=1$ ) and acute renal failure which resolved at discharge ( $n=1$ ). One major complication (death) occurred in the immediate post-intervention period in a patient who presented with an acute massive PE. This patient underwent CDT during which he became increasingly hypoxic and hypotensive requiring intubation. He went into PEA arrest but had return of spontaneous circulation during the initial 24 hours of thrombolysis. He presented for follow-up angiogram which showed persistent thrombus requiring suction thrombectomy. A longer infusion length catheter was exchanged and CDT was continued for an additional 24 hours. After 48 hours of CDT, he experienced one episode of ventricular tachycardia which responded to defibrillation; however, he had PEA again and was placed on ECMO without improvement in his hemodynamics and subsequently passed. No patients undergoing CDT in our study had major hemorrhagic complications.

Clinical success, defined as reported symptomatic improvement was demonstrated in 92.8% of patients who received CDT during their postprocedural hospital course. Thirty-day all-cause mortality rates were comparable between patients that received additional therapy as determined by follow-up angiography and those that did not (2 vs. 1,  $P=0.332$ ).

**Discussion**

Catheter-directed thrombolysis at experienced centers is an evolving therapeutic option for patients with acute massive or submassive PE either as a first-line intervention or for those who have failed or have contraindications to systemic anticoagulation. In the current study, the use of follow-up pulmonary angiography following CDT for symptomatic PE patients identified 11 patients (40.7%) as needing the following additional therapy to remove residual clot burden: extended CDT beyond 24 hours with or without catheter repositioning or exchange, adjunctive mechanical/suction thrombectomy, or a combination of extended CDT and mechanical/suction thrombectomy. As such, more than a third of patients in the current study benefited from next-day pulmonary angiography with respect to additional therapy that ultimately resulted in the desired clinical outcome of resolved right ventricular dysfunction. Our study supports the impact of follow-up angiography on clinical decision making and patient management.

## Discussion

Evaluation of residual clot burden is of importance for achieving optimal outcomes by resolving right heart strain. In a



**Table 2.** Technical variables associated with CDT stratified by the need for additional therapies as identified by follow-up pulmonary angiography for acute massive and submassive PE

	No additional therapy (n=16)	Additional therapy (n=11)	P
Access site			
Internal jugular	2 (12.5)	2 (18.2)	1.000
Femoral	14 (87.5)	9 (81.8)	
No. of catheters			
One	4 (25)	4 (36.4)	0.675
Two	12 (75)	7 (63.6)	
Infusion catheter laterality			
Right	1 (6.3)	4 (36.4)	
Left	2 (12.5)	0	
Bilateral	13 (81.2)	7 (63.6)	
Mean combined infusion length (cm)	18.4±9.4	15.7±5.3	0.477
Mean combined rate of TPA (mg/h)	1.0±0.1	1.0±0.3	0.331
Mean combined rate of heparin (mg/h)	322.7±93.2	357.1±139.7	0.537

Data are presented as mean±standard deviation or n (%).  
CDT, catheter-directed thrombolysis; PE, pulmonary embolism; TPA, tissue plasminogen activator.

meta-analysis of 35 studies and 549 total patients with symptomatic PE, 60% of patients underwent extended thrombolytic infusion (1). The frequency of clinical success, as defined by clinical improvement, was higher in studies in which participants received extended thrombolysis as compared with studies that did not (1). The role of follow-up pulmonary angiography as opposed to other imaging modalities in determining improvement following CDT is unclear. In select institutions, follow-up pulmonary angiography is standard protocol. At other institutions and/or within other specialties, echocardiography and CT angiography are routinely used to assess for clinical improvement after CDT.

Echocardiography is an operator dependent modality that allows for real-time assessment of RV dysfunction and indirect assessment of pulmonary artery pressures. Echocardiography, however, cannot reliably assess residual clot burden within the pulmonary arterial system. While improvement in RV dysfunction and hemodynamics is of importance in the acute setting, a significant percentage of acute PE survivors are also at risk of chronic thromboembolic pulmonary hypertension, with an estimated 4% progressing to develop this condition

with the possible need for lifelong anticoagulation or pulmonary endarterectomy (8, 9). Thus, evaluation of residual clot burden in addition to noninvasive hemodynamic monitoring remains important in both the immediate procedure setting as well as for long-term follow-up. CT angiography is a noninvasive alternative method of evaluating the RV/LV ratio as well as residual clot burden but is subject to technical factors that can alter the quality of the study. Several factors including imaging noise, streak artifact from infusion catheters, respiratory-motion artifact, anatomical, and pathologic considerations influence the quality of CT angiography studies and proper evaluation of thrombus burden (10, 11).

Alternatively, conventional pulmonary angiography allows for real-time evaluation of residual clot burden, PA pressures, and allows for further therapy such as catheter repositioning, exchange, thrombectomy, or continued thrombolysis. Furthermore, conventional angiography remains the gold standard for the diagnosis of acute and chronic PE given its high spatial resolution (12). In patients with persistently elevated PA pressures/abnormal hemodynamics, immediate evaluation of thrombus burden and debulking by mechanical frag-

mentation or aspiration thrombectomy can quickly improve hemodynamics. Follow-up pulmonary angiography is, however, more invasive and time-consuming compared with echocardiography or CT angiography. The value of follow-up pulmonary angiography for evaluating improvement after CDT is controversial and largely limited by a paucity of large studies assessing its utility and role for additional intervention. Our study outcome suggests that the impact of follow-up angiography may outweigh the invasive nature of this diagnostic tool.

Predetermined technical endpoints for thrombolysis vary by institution, but typically include a maximum tPA dose (18–72 mg) and 18–72 hour infusion period (13). Clinical endpoints include improved systolic blood pressure (>100 mmHg), resolving tachycardia (<100 bpm), and decreasing oxygen requirements. Other current standards of measuring improvement following CDT include normalization of RV/LV ratios, PA pressure correction, and improved hemodynamics as seen on echocardiography, CT angiography, or conventional pulmonary angiography (13, 14). Currently there are no studies comparing the significance of these clinical endpoints or imaging modalities in helping to determine the need for further therapy.

In our study, clinical or technical factors were not significantly associated with the need for additional thrombolysis or thrombectomy beyond 24 hours. Specifically, initial and next-day PA pressures as well as preprocedural RV/LV ratios did not differ significantly between cohorts needing further therapy and those that did not. Younger age was seen with significantly higher frequency in the group requiring additional therapy; however, this was of unclear importance and may be the result of a small sample size. One study found that in-hospital mortality was significantly reduced in patients aged 75 or older that underwent CDT, suggesting that CDT may be beneficial in this patient population (15). It remains uncertain which patient populations benefit most from invasive pulmonary angiography.

This study is limited by many factors, namely its small sample size, single institution experience, and retrospective nature. Patients receiving additional therapy were retrospectively compared with their cohorts who did not, which may represent selection bias for more critically ill (or slower to recover) patients returning for

pulmonary angiography. Furthermore, the need for additional therapy as determined by follow-up pulmonary angiography was at the discretion of the interventionalist. As such, a limitation of this study is the inherent bias within clinical judgement among operators. Additionally, noninvasive examinations such as echocardiography or CT angiography was not performed in the cohort returning for pulmonary angiography, limiting the ability of this study to directly compare the ability of the two techniques for predicting the necessity for additional therapy.

In conclusion, follow-up pulmonary angiography is an effective and safe means of assessing improvement and identifying patients needing adjunct therapy in acute PE management. In more than a third of our patients, follow-up angiography resulted in additional therapy to resolve pulmonary arterial hypertension and right heart dysfunction. However, the effectiveness and safety of CDT when compared to systemic therapy remains inadequately studied. Prospective trials of the role of CDT in the management of patients with submassive/massive PE are needed.

#### Conflict of interest disclosure

Osman Ahmed is a speaker for Spectranetics® and medical advisory board member for Bayer®; Bülent Arslan is a speaker and advisory board member for Penumbra®, Medtronic/Covidien®, and speaker for Cook®, W.L. Gore®, Guerbet®, and CR Bard®.

#### References

1. Kuo WT, Gould MK, Louie JD, Rosenberg JK, Sze DY, Hofmann LV. Catheter-directed therapy for the treatment of massive pulmonary embolism: systematic review and meta-analysis of modern techniques. *J Vasc Interv Radiol* 2009; 20:1431–1440. [\[CrossRef\]](#)
2. Wiener R S, Schwartz L M, Woloshin S. Time trends in pulmonary embolism in the United States: evidence of overdiagnosis. *Arch Intern Med* 2011; 171:831–837. [\[CrossRef\]](#)
3. Kuo WT, Sista AK, Faintuch S, et al. Society of Interventional Radiology position statement on catheter-directed therapy for acute pulmonary embolism. *J Vasc Interv Radiol* 2018; 29:293–297. [\[CrossRef\]](#)
4. Piazza G, Hohlfelder B, Jaff MR, et al. A prospective, single-arm, multicenter trial of ultrasound-facilitated, catheter-directed, low-dose fibrinolysis for acute massive and submassive pulmonary embolism: The SEATTLE II Study. *JACC Cardiovasc Interv* 2015; 8:1382–1392. [\[CrossRef\]](#)
5. Kuo WT, Banerjee A, Kim PS, et al. Pulmonary embolism response to fragmentation, embolectomy, and catheter thrombolysis (PERFECT): initial results from a prospective multicenter registry. *Chest* 2015; 148:667–673. [\[CrossRef\]](#)
6. Jaff M, McMurtry MS, Archer SL, et al. Management of massive and submassive pulmonary embolism, iliofemoral deep vein thrombosis, and chronic thromboembolic pulmonary hypertension. *Circulation* 2011; 123:1788–1830. [\[CrossRef\]](#)
7. Banovac F, Buckley DC, Kuo WT, et al. Reporting standards for endovascular treatment of pulmonary embolism. *J Vasc Interv Radiol* 2010; 21:44–53. [\[CrossRef\]](#)
8. Pengo V, Lensing AW, Prins MH, et al. Incidence of chronic thromboembolic pulmonary hypertension after pulmonary embolism. *N Engl J Med* 2004; 350:2257–2264. [\[CrossRef\]](#)
9. Poli D, Miniati M. The incidence of recurrent venous thromboembolism and chronic thromboembolic pulmonary hypertension following a first episode of pulmonary embolism. *Curr Opin Pulm Med* 2011; 17:39–397. [\[CrossRef\]](#)
10. Wittram C, Maher MM, Yoo AJ, Kalra MK, Shepard JA, McLoud TC. CT angiography of pulmonary embolism: diagnostic criteria and causes of misdiagnosis. *Radiographics* 2004; 24:1219–1238. [\[CrossRef\]](#)
11. Ferretti GR, Collomb D, Ravey JN, Vanzetto G, Coulomb M, Bricault I. Severity assessment of acute pulmonary embolism: role of CT angiography. *Semin Roentgenol* 2005; 40:25–32. [\[CrossRef\]](#)
12. Kharat A, Hachulla AL, Noble S, Lador F. Modern diagnosis of chronic thromboembolic pulmonary hypertension. *Thromb Res* 2018; 163:260–265. [\[CrossRef\]](#)
13. Zarghouni M, Charles HW2, Maldonado TS. Catheter-directed interventions for pulmonary embolism. *Cardiovasc Diagn Ther* 2016; 6:651–661. [\[CrossRef\]](#)
14. Kesselman A, Kuo WT. Catheter-directed therapy for acute submassive pulmonary embolism: summary of current evidence and protocols. *Tech Vasc Interv Radiol* 2017; 20:193–196. [\[CrossRef\]](#)
15. Patel N, Patel NJ, Agnihotri K, et al. Utilization of catheter-directed thrombolysis in pulmonary embolism and outcome difference between systemic thrombolysis and catheter-directed thrombolysis. *Catheter Cardiovasc Interv* 2015; 86:1219–1227. [\[CrossRef\]](#)