Diagn Interv Radiol 2024; DOI: 10.4274/dir.2023.232393

BREAST IMAGING

ORIGINAL ARTICLE

Follow-up results of BI-RADS 3 lesions on magnetic resonance imaging: a retrospective study

Özge Aslan
Ayşenur Oktay
Fatih Eroğlu

Ege University Faculty of Medicine, Department of Radiology, İzmir, Turkey

PURPOSE

The categorization of Breast Imaging Reporting and Data System (BI-RADS) 3 lesions is not as clear in magnetic resonance imaging (MRI) as it is in mammography (MG). With the increasing number of MRI scans currently being conducted globally, incidentally detected lesions falling into the probably benign category are frequently being observed. In this study, our aim was to investigate the imaging characteristics and follow-up results of BI-RADS 3 lesions detected by MRI and to determine their malignancy rates.

METHODS

Breast MRI scans performed between January 2010 and January 2020 and classified as BI-RADS 3 lesions were retrospectively analyzed. The study included 216 lesions with known biopsy or surgical excision results or with at least one year of radiological follow-up. We assessed the patients' age, the presence of breast cancer, the follow-up interval, and the imaging findings at the beginning and during the follow-up. Lesions that remained stable, disappeared, or decreased in size and had a benign histopathological diagnosis were classified as benign. Lesions with the histopathological diagnosis of malignancy, identified by either biopsy or surgical excision, were classified as malignant. We determined the malignancy rate based on the histopathology and follow-up results.

RESULTS

Considering the follow-up results of all cases, 8% of lesions were excised, 0.5% decreased in size, 1.4% became enlarged, 17.1% disappeared, and 73% remained stable. The malignancy rate was 2.8%. A significant relationship was found between lesion shape and malignancy, as progression to malignancy was more likely in round lesions than in other types. An irregular margin, heterogeneous enhancement, and kinetic curve (type 2) features were significant for lesion upgrade to malignancy.

CONCLUSION

The malignancy rate in BI-RADS 3 lesions detected by MRI is low and falls within the accepted cancer rate for MG and sonography. Changes in size, morphology, and enhancement pattern should be considered in terms of malignancy development during follow-up. The follow-up intervals should be determined on a case-by-case basis.

KEYWORDS

Probably benign, BI-RADS 3, MRI, breast, cancer

Corresponding author: Özge Aslan

E-mail: dr.ozgeaslan@gmail.com

Received 04 July 2023; revision requested 27 July 2023; last revision received 14 November 2023; accepted 27 December 2023.

Epub: 31.01.2024

Publication date:

DOI: 10.4274/dir.2023.232393

The Breast Imaging Reporting and Data System (BI-RADS) was developed by the American College of Radiology (ACR) with the aim of providing standardized reporting for the radiological evaluation of breast lesions. Its latest edition (the fifth) was published in 2013.[1,2] The BI-RADS 3 category has been defined for lesions initially detected on mammography (MG) with a cancer risk of less than 2%.[1-6] These lesions can be monitored through short-term follow-up to rule out malignancy (at 6, 12, and 24 months), thereby minimizing the risks and expenses associated with invasive tissue sampling in these predominantly benign lesions.[3-5] However, the categorization of BI-RADS 3 lesions is not as clear in magnetic resonance imaging (MRI) as it is in MG.[2,5] Nevertheless, the increased global use of MRI has led to

You may cite this article as: Aslan Ö, Oktay A, Eroğlu F. Follow-up results of BI-RADS 3 lesions on magnetic resonance imaging: a retrospective study Follow-up results of BI-RADS 3 lesions on magnetic resonance imaging: a retrospective study. *Diagn Interv Radiol.* 31 January 2024 DOI: 10.4274/dir.2023.232393 [Epub Ahead of Print].

an increase in the incidental detection of lesions in the probably benign category. A meta-analysis comprising 11 studies conducted by Spick et al.[4] has reported the incidence of BI-RADS 3 lesions in breast MRI to range from 1.2% to 24.3%.

The classification of the BI-RADS 3 category in breast MRI is determined by the interpreting radiologist.[4] For lesions categorized as BI-RADS 3 in MRI, the reported malignancy rates are between 0.2% and 15%.[2,3,7-9] Various studies on BI-RADS 3 lesions in MRI have identified different reasons for performing MRI, including screening for high-risk patients, problem-solving, and breast cancer staging.[4,5]

In the fifth edition of the ACR BI-RADS atlas, probably benign lesions are defined as non-bright on T2-weighted (T2W) MRI and well-circumscribed masses with focal enhancement on contrast-enhanced MRI, distinct from the surrounding parenchyma.[1,5] In cases where the findings may be influenced by hormonal status (e.g., outside the second week of the menstrual cycle or due to external hormone intake), a short-term follow-up examination is recommended at the appropriate time (e.g. during the second week of the menstrual cycle or a few weeks after discontinuing hormone therapy).[1] In MRI, distinguishing suspicious lesions from benign lesions and background enhancement can be challenging, resulting in false positives and unnecessary biopsies.[5,7]

Due to the evolving malignancy rates and distinctive imaging features, the classification of probably benign lesions (BI-RADS 3) in MRI remains a topic of debate. In this study, our aim is to investigate the imaging characteristics and follow-up results of BI-RADS 3 lesions detected by MRI and to determine their malignancy rates.

Main points

- The Breast Imaging Reporting and Data System (BI-RADS) 3 category reported on breast magnetic resonance imaging (MRI) depends on the decision of the evaluating radiologist.
- Probably benign lesions are defined as non-bright on T2-weighted images and well-circumscribed masses with focal enhancement on contrast-enhanced MRI, unlike the parenchymal enhancement in the fifth edition of the American College of Radiology BI-RADS atlas.
- In cases initially defined as BI-RADS 3 and subsequently diagnosed as malignant, the disease can be detected at an early stage through close follow-up.

Methods

This study received ethical approval from the medical research ethics committee of the Ege University Faculty of Medicine, Medical Research Ethics Committee (approval number: 21-4T/57, date: 01.04.2021). Informed consent was obtained from all patients prior to MRI, and no additional approval was necessary, as the study was conducted retrospectively.

Breast MRI scans performed between January 2010 and January 2020 and reported as BI-RADS 3 lesions were retrospectively reexamined using a picture archiving and communication system (Sectra IDS7 Workstation, Sectra AB, Sweden). A total of 159 lesions were excluded, as follows: 131 due to the absence of radiological follow-up findings or pathology results and 28 due to prior neoadjuvant chemotherapy. The study ultimately included 216 patients who either had undergone biopsy or surgical excision or had a minimum of one year of radiological follow-up (Figure 1). Each patient's age, previous or concurrent breast cancer history, and follow-up interval were evaluated. The imaging findings obtained at the initial assessment and during the subsequent follow-up period were reviewed (Figure 2). The radiological images were evaluated by the same radiologist, who had 12 years of experience overall and 5 years of experience in breast radiology. The median age of the patients was 46.50 ± 10.3 years.

The MRI scans were performed using 1.5-Tesla (Siemens Healthineers, Magnetom Amira & Symphony, Erlangen, Germany) and 3-Tesla (Siemens Healthineers, Magnetom Verio, Erlangen, Germany) MRI units. The patients were positioned prone, and their breasts were placed within a dedicated surface breast coil. The MR images were acquired using axial, fat-suppressed, and fast spin-echo T2W imaging sequences, as well as pre-contrast and post-contrast dynamic axial T1W three-dimensional, fat-suppressed, fat-spoiled gradient-echo sequences. For contrast-enhanced sequences, until 2017, a rapid bolus injection of 0.2 mL/kg gadopentetate dimeglumine (Magnevist, Bayer, Berlin, Germany) was administered; since 2017, 0.1 mmol/kg gadobutrol (Gadovist, Bayer, Berlin, Germany) has been used, followed by a 10 mL saline flush at a rate of 2 mL/s through an indwelling intravenous catheter. In MRI examinations, several features were evaluated, including the breast parenchymal pattern and signal characteristics of the lesion on T2W images as well as the lesion size, location, enhancement type, shape, margins, enhancement patterns, and kinetic curve type on dynamic contrast-enhanced images. The presence and size of the lesion were documented on ultrasound (US) and MG images, if any, at baseline and at follow-up.

For the classification of lesions, we considered BI-RADS 3 lesions to be those displaying oval-/round-shaped, circumscribed margins; homogeneous enhancement; and non-suspicious kinetic curves on dynamic contrast-enhanced images.[10-12]

The histopathology results for the lesions that had undergone biopsy or surgical excision were obtained from the hospital information system. Lesions diagnosed as malignant were noted. Lesions with a benign

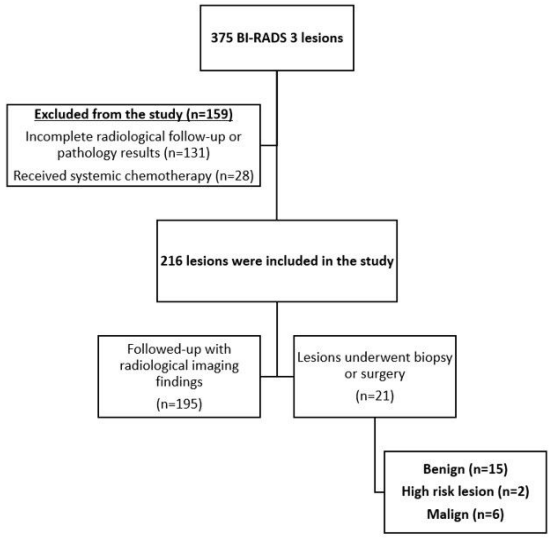

Figure 1. Flowchart of the study. BI-RADS, Breast Imaging Reporting and Data System.

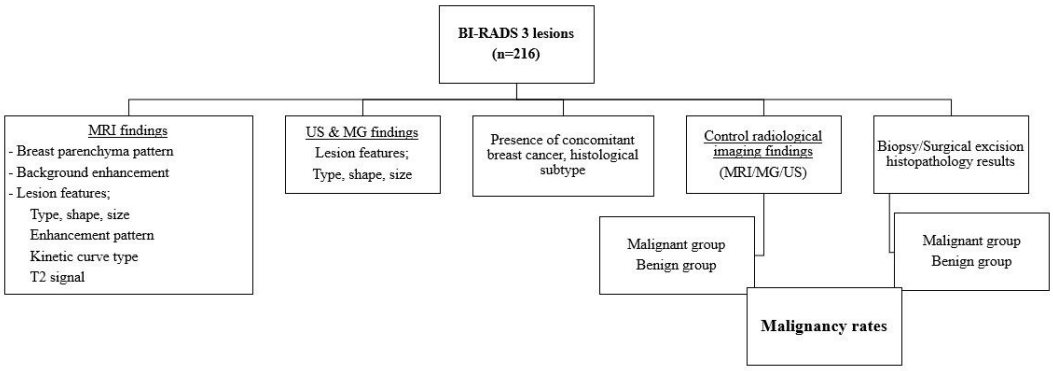

Figure 2. Evaluated parameters. BI-RADS, Breast Imaging Reporting and Data System; MRI, magnetic resonance imaging; US, ultrasonography; MG, mammography.

histopathological diagnosis and those that remained stable, decreased in size, or disappeared within at least one year of follow-up were classified as benign. For all cases, the malignancy upgrade rate was determined based on the histopathology results and follow-up outcomes.

Statistical analysis

The normality of the data distribution was assessed using the Shapiro–Wilk test. Due to the absence of a normal distribution in the data, comparisons between two groups were conducted using the Mann–Whitney U test. For comparisons involving more than two groups, the Kruskal–Wallis test was employed. When significant differences were detected, pairwise comparisons were performed using the Dunn–Bonferroni post-hoc test. Descriptive values were presented as the median (min=max) due to the application of non-parametric tests. The intergroup comparison of categorical data was executed using the chi-square test, Fisher's exact test, and Fisher–Freeman–Halton test. Descriptive values for categorical data were expressed as the frequency (n) and percentage (%).

The significance level for all statistical analyses was set at $\alpha = 0.050$. The SPSS version 25.0 (IBM Corp., Armonk, NY, USA) software package was utilized for data analysis.

Results

The indication for MRI examination was present for local staging of breast cancer in 13 patients, and in the remaining 203 patients, MRI was performed as part of a problem-solving approach for and screening of high-risk women. The lesions were evenly distributed between the right breast (51%) and the left breast (49%). The upper outer quadrant was the most common location, accounting for 25% of the cases. The most common breast parenchymal pattern was type C (67%), and the most common type of background enhancement was minimal enhancement (53%) (Table 1).

In addition to detection by MRI, 18% of the lesions were also detected by MG and 39% by US. Follow-up was primarily performed using MRI in 76% (n = 164) of the cases, while the remaining 24% (n = 52) underwent follow-up with US and MG. Of the 164 lesions followed up with by MRI, 128 (78%) remained stable, and 36 (22%) disappeared. Among the patients monitored by US and MG (n = 52), 16 lesions disappeared, 31 remained stable, and 5 were determined to be benign (fibroadenoma, sclerosing adenosis, and intraductal papilloma) after surgical excision. The median follow-up interval was 18 months (range: 12–120 months).

The median lesion size measured by MRI was 8 mm (min: 3 mm; max: 25 mm). The following types of lesions were observed in MRI: 13.4% were classified as foci, 75.5% as masses, and 11.1% as non-mass enhancements (NMEs) (Table 1).

Among the most common types of masses, 98% were well circumscribed, with the predominant lesion shape being oval (57.1%) and the internal contrast pattern appearing as homogeneous in 68.1% of cases. In the masses, the kinetic curve type was persistent in 86% (type 1), the T2 signal was high in 50%, and the malignancy rate was 3.1%.

All foci were well circumscribed, with 79.3% showing homogeneous enhancement. Additionally, 90% showed no high signal on T2W images. The malignancy rate among the foci was 3.5%.

NMEs were primarily observed as focal contrast enhancements (62.5%), with the majority exhibiting a homogeneous internal enhancement pattern (42%). No malignancy was detected among the NMEs, and the kinetic curve type was consistently persistent (92%), with no high signal observed on T2W images in 67% of cases.

When considering all lesions, the enhancement kinetic curve analysis showed that 87% of the lesions had a persistent enhancement, while 13% had a plateau enhancement (Table 1).

In 54% of the lesions, no distinct findings other than the parenchymal signal were detected on T2W images, while a high signal was observed in the same area as the lesion in 46%. Two patients exhibited a high T2 signal and received a malignant diagnosis; in both cases, the lesion type was identified as a mass.

An accompanying malignant mass was present in 13 patients, with invasive ductal carcinoma being the most common histopathological type (58%). All of the BI-RADS 3 lesions identified in these patients were classified in the benign category; among them, five were determined as benign through surgical excision, two were no longer apparent in follow-up MRI, and six remained stable over a median follow-up period of 34.5 months.

The follow-up results for the BI-RADS 3 lesions gave the following distribution of outcomes: 8% were excised, 0.5% decreased in size, 1.4% became enlarged, 17.1% disappeared, and 73% remained stable (Table 2).

Among the BI-RADS 3 lesions (n = 6) that were diagnosed as malignant, one lesion appeared as a focus, while five lesions showed mass enhancement in MRI. Among the malignant lesions categorized as masses, the shape was oval-lobulated in three patients and round in two patients. Regarding margin

features, two displayed irregular contours, while four exhibited smooth contours. In the internal contrast enhancement patterns, four presented a heterogeneous pattern, while two displayed a homogeneous pattern. In terms of kinetic curves, three lesions demonstrated a persistent pattern, and three followed a plateau pattern. Notably, four malignant lesions did not show a high T2 signal, whereas the other two exhibited high signal intensity.

Core needle biopsies were performed on 13 lesions; of those, 3 were diagnosed as malignant and 10 as benign. Two patients initially diagnosed with benign lesions were later found to have malignancy upon surgical excision (accuracy of biopsy: 84.6%, sensitivity: 100%, specificity: 60%, positive predictive value: 80%, negative predictive value: 100%).

Of the lesions that were surgically excised, 15 were determined to be benign, and 6 were diagnosed as malignant (Table 3). The malignancy upgrade rate was 2.8%.

Our further analysis of the clinical features of the BI-RADS 3 lesions diagnosed as malignant (Table 4) revealed the following findings: One patient presented with bloody nipple discharge during the one-year follow-up. Additionally, new suspicious microcalcifications were detected in two patients, and contour irregularity was observed in two patients on US control. In one patient, the follow-up of a lesion that initially displayed probably benign morphology on US was interrupted due to the novel coronavirus disease-2019 (COVID-19) pandemic. Two years later, the lesion exhibited both a significant increase in size and irregular contours (Figures 3, 4).

Table 1. Magnetic resonance imaging findings

	Follow-up results of the Breast Imaging Reporting and Data System (BI-RADS) 3 lesions			*P*
	Benign group n (%)		Malignant group n (%)	
Breast parenchymal pattern (n = 216)	**A**	11 (5.1)	0 (0)	0.838
	B	43 (20)	2 (0.9)	
	C	140 (64.8)	4 (1.8)	
	D	16 (7.4)	0 (0)	
Background enhancement (n = 216)	**Minimal**	113 (52.3)	2 (0.9)	0.319
	Mild	24 (11.1)	0 (0)	
	Moderate	47 (21.8)	2 (0.9)	
	Marked	26 (12.1)	(0.9)	
Lesion T2 signal (n = 216)	**Low and moderate**	112 (52)	98 (45.3)	0.688
	High	4 (1.8)	2 (0.9)	
Lesion type (n = 216)	**Focus**	28 (13)	(0.4)	1.000
	Mass	158 (73.2)	5 (2.3)	
	Non-mass	24 (11.1)	0 (0)	
Mass shape (n = 163)	**Oval**	92 (56.5)	1 (0.6)	0.020 **Pairwise comparison test:** Lobulated–round *P* = 0.014 Oval–round *P* = 0.004 Oval–lobulated *P* = 0.570
	Lobulated	64 (39.3)	2 (1.2)	
	Round	2 (1.2)	2 (1.2)	
Mass margin (n = 163)	**Smooth**	156 (95.8)	3 (1.8)	0.004
	Irregular	2 (1.2)	2 (1.2)	
Mass enhancement (n = 163)	**Homogeneous**	110 (67.5)	1 (0.6)	0.038 **Pairwise comparison test:** Homogeneous – heterogeneous *P* = 0.015
	Heterogeneous	34 (20.9)	4 (2.4)	
	Rim	2 (1.2)	0 (0)	
	Dark internal septation	12 (7.4)	0 (0)	
Non-mass enhancement (n = 24)	**Homogeneous**	10 (41.7)	0	-
	Heterogeneous	9 (37.5)	0	
	Clumped	5 (20.8)	0	
Kinetic curve type (n = 216)	**Persistent**	185 (88.1)	3 (50)	0.030
	Plateau	25 (11.9)	3 (50)	

Table 2. Follow-up results of the BI-RADS 3 lesions

Follow-up result	Stable n (%)	Decreased in size n (%)	Disappeared n (%)	Enlarged n (%)	Excised n (%)	Total n (%)
Benign group	158 (73.1)	1 (0.5)	37 (17.1)	2 (1)	12 (5.5)	210 (97.2)
Malignant group	-	-	-	1 (0.5)	5 (2.3)	6 (2.8)
Total	158 (73.1)	1 (0.5)	37 (17.1)	3 (1.4)	17 (7.8)	216 (100)

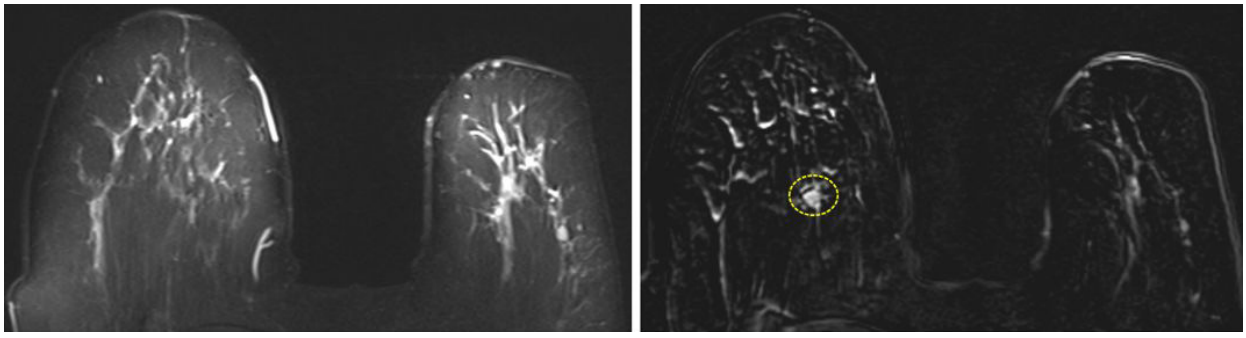

Figure 3. A 69-year-old female. No high signal was observed in the T2-weighted (T2W) image (right side). A heterogeneously enhanced 8-mm diameter mass was visible on the T1-weighted post-contrast subtraction magnetic resonance image (left side). It was categorized as a BI-RADS 3 lesion, and the patient was recommended for a follow-up magnetic resonance imaging after six months.

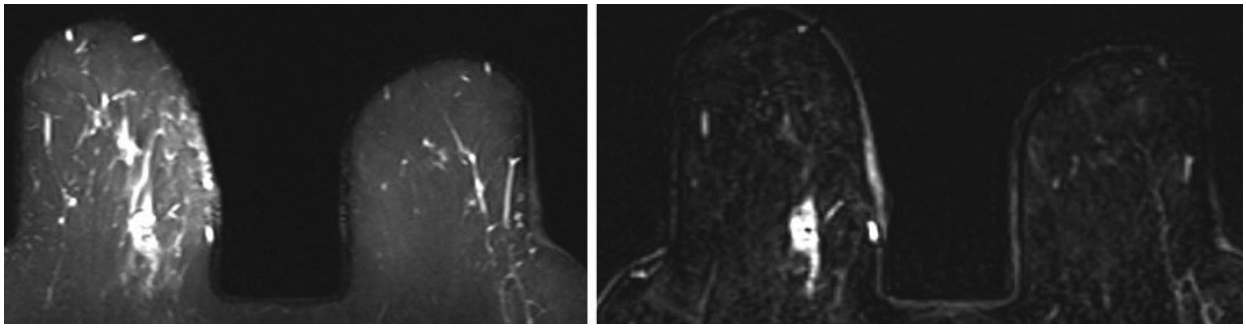

Figure 4. The patient depicted in Figure 3 returned for a follow-up examination two years later, a delay attributed to the novel coronavirus-2019 pandemic. The lesion showed a substantial increase in size and displayed irregular contours on a T2-weighted image (right side) and a T1-weighted post-contrast subtraction magnetic resonance image (left side). The surgical excision histopathology result revealed an encapsulated papillary carcinoma.

Table 3. Histopathological results of the core needle biopsies and the surgical excisions

		n	%
Benign	Sclerosing adenosis	1	5.9
	Fibroadenoma	7	41.2
	Fibrocystic changes	1	5.9
	Atypical intraductal papilloma	2	11.7
Malignant	Invasive lobular carcinoma	1	5.9
	Ductal carcinoma in situ	3	17.6
	Invasive ductal carcinoma	1	5.9
	Encapsulated papillary carcinoma	1	5.9
	Total	17	100

When considering all lesion types, no statistically significant association was found between lesion localization, lesion diameter, T2 signal, and lesion type parameters for the possibility of upgrading to malignancy ($P > 0.050$). No significant relationship was observed between patient age and lesion upgrade to malignancy ($P = 0.084$).

A significant difference was evident between lesion shape and malignancy, as a progression to malignancy was more likely for round lesions than for lesions of other shapes ($P = 0.006$) (Table 1). An irregular margin, heterogeneous enhancement, and kinetic curve (type 2) features were significant for a lesion upgrade to malignancy ($P = 0.005$, $P = 0.015$, and $P = 0.030$, respectively) (Table 1).

An analysis of the relationship between the characteristics of masses and malignancy revealed significant associations between lesion shape, mass margins, internal enhancement patterns, and kinetic curve type ($P = 0.020$, $P = 0.004$, $P = 0.038$, and $P = 0.021$, respectively) (Table 1). No significant relationship was observed between the T2 signal and malignancy in masses ($P = 0.682$).

No malignancies were observed in NMEs; therefore, no statistical analysis of the variables could be conducted.

No significant differences were found between the lesion margin, internal enhancement pattern, and T2 signal in foci ($P > 0.050$).

Discussion

In this study, the malignancy rate of BI-RADS 3 lesions in MRI was 2.8%. The use of the BI-RADS 3 classification in MRI, despite the absence of specific morphological and kinetic features, results in a short interval follow-up in clinical practice.[3] Therefore BI-RADS 3 category in MRI assessment should be used precisely for increasing the sensitivity of the radiologist toward detecting early stage breast cancer and reducing the occurrence of unnecessary benign biopsies.[11] The prevalence of incidentally detected BI-RADS 3 lesions has increased due to the recommendation by the ACR for annual breast MRI control in patients with a lifetime risk of breast cancer above 20%.

The reported malignancy rate of BI-RADS 3 lesions seen in MRI varies widely, ranging from 0.5% to 10.1%.[3,4,6] One meta-analysis involving 2,183 lesions reported a malignancy upgrade rate of 50/2,183 and a notably higher malignancy rate in non-mass lesions.[4] Lourenco et al.[9] reported a malignancy rate of 2.4%, with the most common lesion form being a mass (49.1%) and the highest ma-

Table 4. Characteristics of the BI-RADS 3 lesions diagnosed as malignant at follow-up

Diameter of lesions (mm)	Reason for biopsy and surgical excision	Histopathological diagnosis
15	Bloody nipple discharge developing on follow-up	DCIS (low grade)
4	Suspicious microcalcifications added to the same area on follow-up	IDC
6	Mild contour irregularity developing on follow-up	IDC
8	Suspicious microcalcifications added to the same area on follow-up	ILC + LCIS
12	Enlargement of the nodule and subsequent structural distortion	IDC
8	Size increase and contour irregularity in the second year, which could not be followed up on due to the novel coronavirus-2019 pandemic	Encapsulated papillary carcinoma

DCIS, ductal carcinoma in situ; IDC, invasive ductal carcinoma; ILC, invasive lobular carcinoma; NAC, neoadjuvant chemotherapy; LCIS, lobular carcinoma in situ.

lignancy rate associated with NME being at 3.8%. Nguyen et al.[10], in their review, found a malignancy rate of 2% or lower for foci, 1.8% for mass lesions, and over 2% for NMEs. In our series, the malignancy upgrade rate was 2.8%, and the lesions diagnosed as malignant were predominantly in the form of mass enhancement. We identified a malignancy rate of 3.5% in foci and 3.1% in masses, whereas we did not detect any malignancy in lesions characterized by NMEs. The difference between our findings and the literature might reflect the fact that 75.5% of the 216 lesions in our study exhibited mass enhancement.

Regarding foci, Eby et al.[3] reported that lesions displaying persistent kinetic curves could potentially be benign. One study conducted by Ha et al.[13] on 136 foci indicated that kinetic evaluation was inconclusive. It further suggested that the absence of T2 hyperintensity and the presence of a newly developing or an enlarging focus would be a significant indicator of malignancy. In our study, 1 of the 29 foci was malignant, had no high T2 signal, showed heterogeneous enhancement, and had a persistent kinetic curve.

In certain studies, oval and round shapes have been grouped together for the assessment of malignancy. However, the review by Nguyen et al.[10] highlighted that a round shape holds significance in relation to malignancy. In our study, we identified a significant relationship between a round shape and malignancy ($P = 0.020$).

Our data were insufficient to draw conclusions concerning the relationship between lesion internal enhancement patterns and malignancy; therefore, considering this parameter as a factor in the decision-making process would be ill advised.[10] In the present study, we noted a significant distinction in the pairwise comparisons between the internal enhancement pattern of mass lesions and malignancy, particularly between homogeneous and heterogeneous types. Specifically, lesions with heterogeneous enhancement exhibited a higher malignancy rate ($P = 0.015$).

As malignancy was not identified among our patients with NMEs, we could not conduct any assessments in this regard. Grimm et al.[2] reported a greater prevalence of malignancy in lesions displaying NME and in those exhibiting inhomogeneous internal contrast enhancement. However, the data on NME kinetic properties are insufficient; therefore, we recommend looking at the distribution first.[10,11] The literature underscores that a linear or segmental distribution in lesions with NME is indicative of malignancy.[10,11,14] Among our NME lesions, only one displayed a linear distribution, while the rest were focal and regional. Importantly, all of these lesions were categorized as benign.

The Eastern Cooperative Oncology Group–ACR Imaging Network (ACRIN) 1141 trial advised classifying patients with and without lesions with hyperintense T2 signal as BI-RADS 3 if the lesions exhibited well-defined and homogeneous enhancement.[10,12] Even though the lesions with a high T2 signal were not included in the BI-RADS 3 category according to the latest ACR recommendation, lesions with a high T2 signal generally exhibit a lower malignancy rate.[10] Grimm et al.[15] demonstrated a malignancy rate below 2% for lesions exhibiting a high T2 signal. Conversely, Price et al.[16], who evaluated lesion characteristics within the BI-RADS 4 category, indicated that T2 hyperintensity is not a decisive characteristic. In our study, we did not identify any significant difference between the T2 signal and malignancy. The combined utilization of kinetic and morphological features provides support in the assessment for malignancy.[10]

Due to the high incidence of detecting additional cancers in newly diagnosed breast cancers, caution is needed when classifying lesions identified in MRI scans as BI-RADS 3 when the scans are performed for local staging.[17] The BI-RADS 3 category should not be applied in the absence of typical, likely benign findings or when lesion characterization cannot be executed.[11] Lee et al.[18] reported a malignancy rate of 3.5% for well-defined and rapidly enhancing lesions identified in MRI scans performed for local staging. Among the 13 MRI scans taken for local staging in the present study, all BI-RADS 3 lesions were categorized as benign and exhibited a persistent kinetic curve.

The malignancy rate in BI-RADS 3 lesions detected by MRI is generally low and falls within the accepted range for cancer rates observed in MG and US. Except for a malignancy in one patient who could not be followed up with due to the COVID-19 pandemic, the malignancies detected in the remaining five patients in our study were *in situ* and early stage cancers. The literature suggests that BI-RADS 3 lesions are commonly observed in the scans of high-risk patients and that their malignancy rates may be higher.[9,19] Our findings pointed to the importance of exercising caution during the follow-up of BI-RADS 3 lesions detected in high-risk patients and to the need for close monitoring for any new findings that may arise.

The utilization of second-look US in conjunction with MRI is a practical approach for the diagnosis and follow-up of lesions detected in MRI.[4,20,21] This method allows for further evaluation of the identified lesions, and subsequent follow-up can be performed using US.[10] Additionally, if necessary, core needle biopsy can be readily obtained under US guidance for histopathological diagnosis. In our study, lesions were identified during a second-look US in 84 patients. Among those patients, five individuals received a malignant diagnosis through biopsy and surgical excision, as suspicions escalated due to the margin characteristics of the lesions. Moreover, 37 patients exhibited probably benign findings, and they were subsequently monitored with ultrasonography (with a mean follow-up period of 33 months).

For the management of BI-RADS 3 lesions, which have variable malignancy rates, the literature recommends a total follow-up period of 24 months.[4,21] The initial follow-up

MRI examination is conducted within six months; if the lesion remains stable, the patient's follow-up continues, and a repeat MRI is performed after 12 months. If no concerning changes are noted, the lesion is downgraded to the BI-RADS 2 category.[10] However, any increase in size, morphological change, or appearance of additional suspicious findings during follow-up should be further evaluated with a biopsy.[21] One important point to note is that in the follow-up of lesions with a benign diagnosis from MRI-guided biopsies, approximately 8%–12% may have insufficient sampling, and 14%–18% may ultimately receive a malignant diagnosis; moreover, a false negative rate of 2.5% has been reported in MRI-guided biopsies.[21,22] These findings highlight the importance of careful monitoring and appropriate management of BI-RADS 3 lesions to ensure accurate diagnosis and timely intervention, if necessary.

Sadowski and Kelcz,[23] who studied 68 patients, identified four malignancies within a two-year follow-up period, leading to the recommendation of a comprehensive two-year follow-up interval. The ACRIN 6667 trial reported one malignancy (0.9%) among 106 patients during a two-year follow-up period, and this was attributed to the consistent experience level of the evaluating radiologist group.[24] In our study, we observed that the majority of patients with BI-RADS 3 lesions showed early stage *in situ* cancer during follow-up, with suspicious findings added at yearly intervals. We support the recommended follow-up intervals of six months, one year, and two years for BI-RADS 3 lesions detected in MRI, as suggested by the ACR.[1] Based on our results, we recommend a more careful evaluation in terms of malignancy, particularly for masses with a rounded shape, irregular contours, and heterogeneous enhancement. Considering the low malignancy rate of these lesions, shorter follow-up intervals in appropriate cases may help to reduce the number of unnecessary biopsies.

Our study had several limitations. One was that it was designed retrospectively, with a follow-up period of less than 24 months for some patients. Additionally, breast MRI scans were performed for different purposes, and the imaging quality varied due to the use of different MR devices (1.5 and 3 Tesla). Moreover, not all imaging modalities were available for all patients at their baseline and follow-up evaluations. Although some patients were not evaluated by breast MRI, they were assessed using other modalities, such as US or MG, providing consistency in the control evaluations. Diffusion-weighted MR images were not included in the study due to their unavailability for all patients. Since the BI-RADS 3 lesions were evaluated by a single radiologist, we were unable to evaluate interobserver consistency. Future prospective studies that examine a larger number of BI-RADS 3 lesions, include all imaging modalities, and use longer follow-up periods are needed to establish better clinical guidance and follow-up strategies.

In conclusion, the rising global utilization of breast MRI has created a demand for evidence-based standardized evaluation protocols for MRI BI-RADS 3 outcomes, similar to those established for MG and US. Assigning a classification of MRI BI-RADS 3 can pose challenges and might vary among radiologists and diagnostic centers. During follow-up, changes in size, morphology, and enhancement patterns are important potential indicators of malignancy development. Follow-up intervals should be determined on a case-by-case basis, taking these factors into account.

Conflict of interest disclosure

The authors declared no conflicts of interest.

References

1. American College of Radiology Breast Imaging Reporting and Data System (BI-RADS). 5th ed. Reston, VA: American College of Radiology; 2013. [CrossRef]
2. Grimm LJ, Anderson AL, Baker JA, et al. Frequency of malignancy and imaging characteristics of probably benign lesions seen at breast MRI. *AJR Am J Roentgenol.* 2015;205(2):442-447. [CrossRef]
3. Eby PR, DeMartini WB, Gutierrez RL, Saini MH, Peacock S, Lehman CD. Characteristics of probably benign breast MRI lesions. *AJR Am J Roentgenol.* 2009;193(3):861-867. [CrossRef]
4. Spick C, Bickel H, Polanec SH, Baltzer PA. Breast lesions classified as probably benign (BI-RADS 3) on magnetic resonance imaging: a systematic review and meta-analysis. *Eur Radiol.* 2018;28(5):1919-1928. [CrossRef]
5. Panigrahi B, Harvey SC, Mullen LA, et al. Characteristics and outcomes of BI-RADS 3 lesions on breast MRI. *Clin Breast Cancer.* 2019;19(1):e152-e159. [CrossRef]
6. Spick C, Szolar DH, Baltzer PA, et al. Rate of malignancy in MRI-detected probably benign (BI-RADS 3) lesions. *AJR Am J Roentgenol.* 2014;202(3):684-689. [CrossRef]
7. Hambly NM, Liberman L, Dershaw DD, Brennan S, Morris EA. Background parenchymal enhancement on baseline screening breast MRI: impact on biopsy rate and short-interval follow-up. *AJR Am J Roentgenol*. 2011;196(1):218-224. [CrossRef]
8. Aslan O, Oktay A, Yeniay L. Evaluation of the effects of neoadjuvant chemotherapy on probably benign breast lesions with MRI: report of two cases. *Ege Journal of Medicine.* 2022;61(2):298-301. [CrossRef]
9. Lourenco AP, Chung MT, Mainiero MB. Probably benign breast MRI lesions: frequency, lesion type, and rate of malignancy. *J Magn Reson Imaging.* 2014;39(4):789-794. [CrossRef]
10. Nguyen DL, Myers KS, Oluyemi E, et al. BI-RADS 3 assessment on MRI: a lesion-based review for breast radiologists [published correction appears in J Breast Imaging. 2023;5(3):e3-e12]. *J Breast Imaging* 2022;4(5):460-473. [CrossRef]
11. Lee KA, Talati N, Oudsema R, Steinberger S, Margolies LR. BI-RADS 3: Current and future use of probably benign. *Curr Radiol Rep.* 2018;6(2):5. [CrossRef]
12. Grimm LJ, Mango VL, Harvey JA, Plecha DM, Conant EF. Implementation of abbreviated breast MRI for screening: AJR Expert Panel Narrative Review. *AJR Am J Roentgenol*. 2022;218(2):202-212. [CrossRef]
13. Ha R, Sung J, Lee C, Comstock C, Wynn R, Morris E. Characteristics and outcome of enhancing foci followed on breast MRI with management implications. *Clin Radiol.* 2014;69(7):715-720. [CrossRef]
14. Kim JA, Son EJ, Youk JH, et al. MRI findings of pure ductal carcinoma in situ: kinetic characteristics compared according to lesion type and histopathologic factors. *AJR Am J Roentgenol.* 2011;196(6):1450-1456. [CrossRef]
15. Grimm LJ, Enslow M, Ghate SV. Solitary, Well-circumscribed, T2 hyperintense masses on MRI have very low malignancy rates. *Journal of Breast Imaging*. 2019;1(1):37-42. [CrossRef]
16. Price ER, Sickles EA, Yitta S, et al. Use of the probably benign (BI-RADS category 3) assessment for masses on breast MRI: Is it transferable to general clinical practice? *Breast J.* 2018;24(2):109-114. [CrossRef]
17. Liberman L, Morris EA, Kim CM, et al. MR imaging findings in the contralateral breast of women with recently diagnosed breast cancer. *AJR Am J Roentgenol*. 2003;180(2):333-341. [CrossRef]
18. Lee JY, Jang M, Kim SM, Yun B, Jang JY, Ahn HS. Preoperative magnetic resonance imaging characteristics of oval circumscribed fast enhancing lesions in patients with newly diagnosed breast cancer. *Medicine (Baltimore).* 2018;97(19):e0704. [CrossRef]
19. Liberman L, Morris EA, Benton CL, Abramson AF, Dershaw DD. Probably benign lesions at breast magnetic resonance imaging: preliminary experience in high-risk women. *Cancer.* 2003;98(2):377-388. [CrossRef]

20. Spick C, Baltzer PA. Diagnostic utility of second-look US for breast lesions identified at MR imaging: systematic review and meta-analysis. *Radiology*. 2014;273(2):401-409. [CrossRef]

21. Lee KA. Breast Imaging Reporting and Data System category 3 for magnetic resonance imaging. *Top Magn Reson Imaging*. 2014;23(6):337-344. [CrossRef]

22. Li J, Dershaw DD, Lee CH, Kaplan J, Morris EA. MRI follow-up after concordant, histologically benign diagnosis of breast lesions sampled by MRI-guided biopsy. *AJR Am J Roentgenol*. 2009;193(3):850-855. [CrossRef]

23. Sadowski EA, Kelcz F. Frequency of malignancy in lesions classified as probably benign after dynamic contrast-enhanced breast MRI examination. *J Magn Reson Imaging*. 2005;21(5):556-564. [CrossRef]

24. Weinstein SP, Hanna LG, Gatsonis C, Schnall MD, Rosen MA, Lehman CD. Frequency of malignancy seen in probably benign lesions at contrast-enhanced breast MR imaging: findings from ACRIN 6667. *Radiology*. 2010;255(3):731-737. [CrossRef]